

---

Electronic Thesis and Dissertation Repository

---

11-13-2020 3:30 PM

## An Exploration of Facial Skin Scarring, Its Impact and Contemporary Evaluation

Michael G. Brandt, *The University of Western Ontario*

Supervisor: Doyle, Philip C., *The University of Western Ontario*

Co-Supervisor: Moore, Corey C, *The University of Western Ontario*

A thesis submitted in partial fulfillment of the requirements for the Master of Science degree in Health and Rehabilitation Sciences

© Michael G. Brandt 2020

Follow this and additional works at: <https://ir.lib.uwo.ca/etd>

 Part of the [Dermatology Commons](#), [Oncology Commons](#), [Otolaryngology Commons](#), and the [Plastic Surgery Commons](#)

---

### Recommended Citation

Brandt, Michael G., "An Exploration of Facial Skin Scarring, Its Impact and Contemporary Evaluation" (2020). *Electronic Thesis and Dissertation Repository*. 7501.  
<https://ir.lib.uwo.ca/etd/7501>

This Dissertation/Thesis is brought to you for free and open access by Scholarship@Western. It has been accepted for inclusion in Electronic Thesis and Dissertation Repository by an authorized administrator of Scholarship@Western. For more information, please contact [wlsadmin@uwo.ca](mailto:wlsadmin@uwo.ca).

## Abstract

Facial skin cancer secondary to surgical treatment may be distressing due to the malignancy itself and from the consequences of its treatment. A visible postsurgical scar is an obvious reminder of the condition. This investigation sought to broaden our understanding of facial scarring and develop a novel tool for its objective evaluation. To this end, skin cancer as the most common etiology of facial scarring was reviewed. The scar scale literature was evaluated in the context of assessing scars through a biopsychosocial lens. Finally, the development of a novel scar scale was presented. Thirty-four individuals completed 13,056 ratings using a novel scar scale – the Scar Camouflage Scale (SCS). Preliminary data demonstrated intra-rater agreement of 0.74 - 0.92 and between-rater agreement of 0.78 - 0.96. In conclusion, through rigorous methodology this investigation provides preliminary support for the establishment and use of the Scar Camouflage Scale (SCS). These results provide the empiric basis for wholistic scar evaluation.

*Keywords:* Skin Cancer, Non-melanoma, Facial Scar, Scar Scale, Scar Evaluation

## Summary for a Lay Audience

Facial skin cancer is an anxiety provoking condition. Not only is the diagnosis distressing, but so too is the consequence of its treatment which is most commonly surgery. Regardless of location, every surgery will result in some form of scarring. When this affects the face, scarring is a visible daily reminder of the condition, one that may also impact one's physical appearance and body image.

Many factors contribute to how a scar impacts an individual's body image. Few research studies have been able to holistically understand these factors, or determine how the scar itself contributes to the person's overall body image and self-perception. One of the main difficulties lies in the way scars are currently evaluated. The research conducted has been somewhat inconsistent and we remain without a standardized way to measure scars.

This investigation sought to improve our understanding of facial scarring and develop a new scar measurement tool. To achieve these goals, we reviewed the most common reason that an individual might acquire a facial scar – facial skin cancer. We then assessed how scars affect a person relative to their psychological and social impact. To this end, we reviewed all relevant literature and aimed to place these in the context of what is termed the “biopsychosocial” model of health. Finally, we presented the results of a study that sought to develop a new scar scale called the Scar Camouflage Scale (SCS).

The results of this study demonstrate that individuals can reliably measure scars using the SCS, even when different individuals measure the same scar. These data

provide the necessary evidence to support further research using the SCS and apply this research to help understand the comprehensive impact of facial scarring.

## Co-Authorship Statement

### Co-Authorship

I hereby declare that this thesis incorporates material that is result of joint research, as follows: Chapter 2 of the thesis was co-authored with Dr. Corey Moore. In all cases, the key ideas, primary contributions, and writing were performed by the author, and the contribution of Dr. Corey Moore was primarily through the provision of clinical photographs, feedback of ideas, and editing of the manuscript.

I certify that, with the above qualification, this thesis, and the research to which it refers, is the product of my own work.

### Previous Publication

This thesis includes one original paper that has been previously published/submitted for publication in peer reviewed journals, as follows:

Thesis Chapter	Publication title/full citation	Publication status
Chapter 2	Brandt, M. G., Moore, C. C. (2019). Nonmelanoma Skin Cancer. Facial plastic surgery clinics of North America, 27(1), 1-13.	Published

I certify that I have retained permission from the copyright owner(s) to include the above published material(s) in my thesis. I certify that the above material describes work completed during my registration as a graduate student at Western University

## Acknowledgements

I wish to express my sincere appreciation to my friend and supervisor, Dr. Philip Doyle, who has guided and encouraged me through this and many other projects. His kindness, integrity, and passion have been a source of inspiration and academic curiosity. I can confidently attest that without his persistence and compassion, this project would not have been realized.

I am especially indebted to Dr. Corey Moore. As my teacher and mentor, he has taught me more than I could ever give him credit for here. From the day we first met, he has motivated my clinical passions and inspired creativity and innovative problem solving. I wish to thank him for his friendship, guidance, and incredible sense of humor.

I wish to thank my patients for their photos, feedback, and the humbling opportunity to share in their most intimate challenges. I continue to learn and grow from each individual patient encounter. Their courage and resiliency in the face of adversity compels me to be a better physician and surgeon.

This project would not have been possible without the willingness of so many gracious participants. I am forever grateful for their altruism.

I would like to thank my parents, who have always supported and motivated me. Much of my passion for research stems from my late father who always encouraged analysis and critical appraisal and once commented that he always wished he could “do scientific research”.

Finally, and most importantly, I wish to thank my loving and supportive wife, Naomi, and my three wonderful children, Eden, Levi and Yael, who provide unending

support and inspiration. Nobody has taught me more about love, compassion, humility, and the true meaning of life.

## Table of Contents

Abstract .....	i
Summary for a Lay Audience .....	ii
Co-Authorship Statement .....	iv
Acknowledgements .....	v
List of Tables .....	xi
List of Figures .....	xii
Chapter 1: Introduction and Background .....	1
Introduction .....	1
Impact of Facial Skin Scarring .....	1
Objective Scar Scaling .....	3
Statement of Problem .....	5
Chapter 2: Contemporary Management of Non-Melanoma Skin Cancer .....	6
Keratinocyte Carcinomas .....	6
Aetiology .....	7
Clinical Features and Work Up .....	9
Basal Cell Carcinoma .....	10
Squamous Cell Carcinoma .....	12
Management .....	13
Biopsy .....	13
Resection of the Primary Malignancy .....	13
Incomplete Excisions and Aggressive Features on	
Pathology .....	14



Advanced Disease .....	15
Less Common Non-Melanoma Skin Cancers .....	16
Merkel Cell Carcinoma .....	16
Clinical Features and Work-up .....	16
Management .....	17
Adnexal Carcinomas of the Skin .....	19
Sarcomas of the Skin .....	23
Dermatofibrosarcoma protuberans (DFSP) .....	24
Clinical Features and Work-up .....	24
Management .....	25
Atypical Fibroxanthoma .....	25
Clinical Features and Work-up .....	26
Management .....	26
Angiosarcomas .....	27
Clinical Features and Work-up .....	27
Management .....	28
Summary .....	28
Chapter 3: ICF and Skin Scarring .....	29
Skin Scarring through the ICF model .....	29
Contemporary Objective Scar Evaluation .....	31
Visual Analog Scaling .....	32
The Patient's Perspective .....	33
Social Impairment .....	33

Summary: The Need for a Biopsychosocial Lens .....	34
Chapter 4: Preliminary Reliability Analysis of a Novel Scale for the Objective	
Evaluation of Linear Scars .....	36
Introduction .....	36
Literature Review and Critical Appraisal .....	36
Objective .....	38
Methods .....	38
Participants .....	38
Sample size calculation .....	39
Design .....	39
Phase 1: Scale Development .....	39
Phase 2: Scar Evaluation Automation .....	45
Phase 3: Scar Evaluation .....	46
Procedure .....	47
Outcome Measures and Statistical Analysis .....	48
Results .....	49
Discussion .....	53
Conclusions .....	57
Chapter 5: Conclusions and Bringing it all Together .....	58
Skin Cancer .....	58
Facial Scarring .....	59
Scar Scaling .....	59
Clinical Implications .....	61

Directions for Future Research .....	62
Limitations of the Present Project .....	64
Summary .....	65
References .....	67
Appendix A: Health Sciences Research Ethics Board Approval.....	81
Curriculum Vitae .....	82

## List of Tables

	Page
Table 2.1: Risk factors for the development of Keratinocyte Carcinomas .....	8
Table 2.2: Common Clinical Features of Keratinocyte Carcinomas .....	9
Table 2.3: Eccrine and Apocrine Gland Carcinomas .....	20
Table 2.4: Carcinomas of the Hair Follicle .....	22
Table 2.5: Carcinomas of the Sebaceous Glands .....	23
Table 4.1: Scar Scale Dimensions .....	42
Table 4.2: Scar Photo Range of Responses .....	51
Table 4.3: Within-rater agreement for the eight scaled dimensions .....	51
Table 4.4: Between-rater agreement for the eight scaled dimensions .....	52
Table 4.5: Comparison of Scar Camouflage Scale to other Scar Rating Scales .....	55
Table 5.1: Scar Evaluation Dimensions .....	60

## List of Figures

	Page
Figure 1: Obvious Upper Lip / Cheek Scar .....	4
Figure 1.2: Well-Camouflaged Left Upper Eyelid Scar .....	4
Figure 2.1: Nodular BCCs .....	10
Figure 2.2: Superficial BCCs .....	11
Figure 2.3: Sclerosing BCCs .....	11
Figure 2.4: Cutaneous SCCs .....	12
Figure 2.5: Merkel Cell Carcinomas .....	17
Figure 4.1: ScARS – Scar Rating Software .....	46
Figure 4.2: Mean Scar Photo Ratings .....	50

## Chapter 1: Introduction and Background

### Introduction

Non-melanoma skin cancer is the most common form of cancer with an estimated annual incidence of 80,000 cases in Canada per year (Canadian Cancer Society, 2014). The head and neck regions are the most common areas of the body affected (Norval et al., 2014). Given the visibility of a skin cancer lesion on the face, it is not surprising that these lesions result in some form of facial disfigurement. A team of investigators at Johns Hopkins University (Baltimore, Maryland, USA) characterized this facial disfigurement an “attractiveness penalty” – largely influenced by the size, depth and location of the facial lesion (Cassileth et al., 1983; Godoy et al., 2011). In addition to the “attractiveness penalty”, individuals with facial lesions have perceived negative affect resulting in an overall “social penalty” that decreases observer comfort when conversing with these individuals socially (Dey, Ishii, Byrne, et al., 2015). Accordingly, removal of the skin cancer and subsequent repair of the removal defect is critical to normalizing these individuals’ appearance and restoring their sense of well-being and social functioning (Godoy et al., 2011).

### Impact of Facial Skin Scarring

Like all surgery, removal of a skin cancer and repair of the subsequent defect results in some degree of surgical scarring. A paper published by Sobanko and colleagues (2015) reviews the impact of skin cancer vis-à-vis an individual’s appearance (Sobanko et al., 2015). To summarize, individuals with a facial scar are stigmatized and more likely to be judged as dysfunctional, dishonest, unsuitable for employment, unintelligent, and unattractive (Borah & Rankin, 2010; Ishii et al., 2009; Kim et al., 2013; Rankin &

Borah, 2003; Sobanko et al., 2015). Perceived stigma by those with a facial lesion or scar can result in an impairment of communication, and restrictions of personal relationships in addition to social and vocational activities (Brown et al., 2010; Sobanko et al., 2015). Importantly, it is the individuals' own subjective perception of their scar visibility and not their observed degree of scarring that directly impairs their psychosocial functioning (Brown et al., 2010; Sobanko et al., 2015). Thus, skin cancer surgery often results in appearance-related anxiety resulting in impairments of quality of life and financial stability – with many going on employment disability due to the psychosocial burden of disfigurement (Sobanko et al., 2015). Finally, facial disfigurement in the form of a scar is so distressing that >50% of adults would risk a 7% chance of death, and more than 13% of adults would accept a 30-45% risk of death, to obtain a “normal” face (Borah & Rankin, 2010; Sobanko et al., 2015).

The burden of facial skin cancer is substantial. Facial skin cancer not only imparts an “attractiveness penalty” in and of itself, but the resultant scar from its removal may also perpetuate psychosocial impairment due to a perceived facial disfigurement. It is not surprising that a well-executed reconstruction following the removal of a facial skin cancer can substantially improve an individual's overall quality of life (Dey, Ishii, Boahene, et al., 2015). But what constitutes a “well-executed reconstruction”? This largely boils down to achieving a “good scar”. The difficulty herein is that a “good scar” is similar to the perception of “talent”; you know a “good scar” when you see it – or rather when you do not see it. Furthermore, it is impossible to ignore the personal factors and context of the individual affected by the scar. A young facial model may be severely traumatized by a small objectively minimal facial scar whereas an older individual with

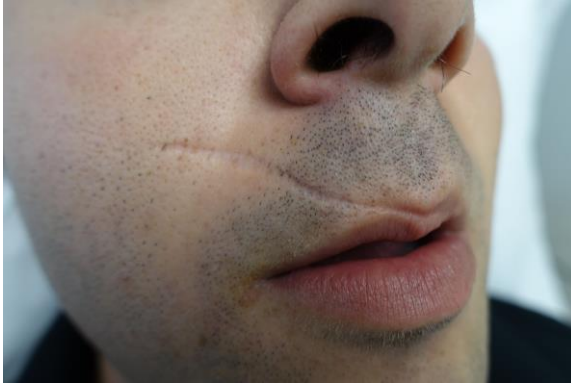substantial facial hair may be relatively unfazed by even a large objectively obvious facial scar. It is the delicate balance of objective scar features, personal factors, and the overall context of the individual affected that truly determine the impact of a facial scar and its burden to the individual. To add to this complexity, a paucity of consistency exists in the objective scar evaluation literature (Durani et al., 2009).

### **Objective Scar Scaling**

When reviewing the scar scaling literature (Durani et al., 2009), a point of disparity relates to which scar features should be evaluated and how they each contribute to the camouflage of the scar and its overall impact on an individual's facial appearance. In fact, without a clear understanding of which scar dimensions need to be evaluated and the mechanism to evaluate them, the logical progression of determining the association of each scar dimension on overall scar camouflage or acceptability cannot be done. What has been evaluated thus far are variations on scar dimensions which include how wide or stretched a scar appears, its height relative to the surrounding skin, its discolouration relative to the surrounding skin, any irregularities in its appearance or distortion of surrounding structures, and any evidence of surgery – i.e., suture marks. Figures 1.1 and 1.2 illustrate examples of poorly camouflaged and well-camouflaged scars, respectively.

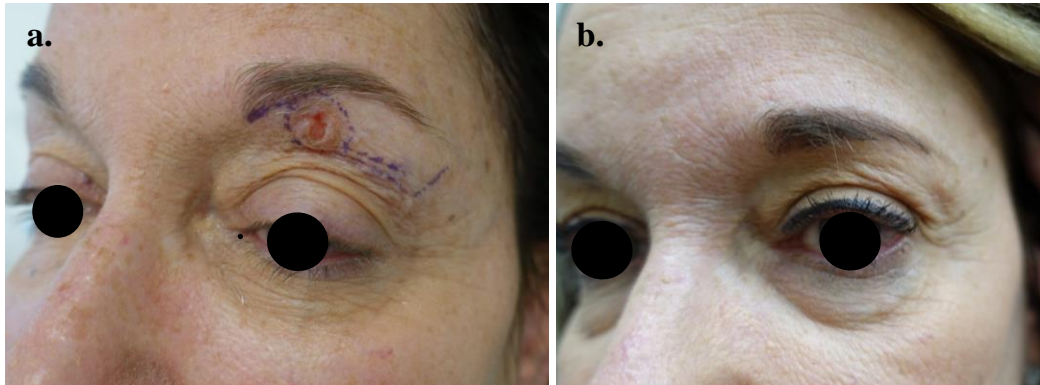


**Figure 1.1:** *Obvious Upper Lip/Cheek Scar*



Note. A poorly camouflaged scar of the right cheek and upper lip many years following a traumatic facial injury.

**Figure 1.2:** *Well-Camouflaged Left Upper Eyelid Scar: (a) prior to and (b) 3-months following surgical excision*



Note. Purple markings indicate incision lines for removal and reconstruction.

The previously described scar dimensions have been defined in various forms in the aforementioned efforts of generating an empirically validated objective scar evaluation scale. The resultant scales from this body of research have included the Vancouver Scar Scale, Patient and Observer Scar Scale, Manchester Scar Scale, Stony Brook Scar Evaluation Scale, and SCAR scale (Durani et al., 2009; Idriss & Maibach,

2009; Perry et al., 2010; Roques & Téot, 2007; Vercelli et al., 2003). While each of these scales demonstrates empiric reliability, they vary in the dimensions being scaled and the methods used to scale these dimensions (Brandt et al., 2009; Perry et al., 2010). Thus, we remain without a reliable tool to objectively characterize observed scar outcomes.

### **Statement of Problem**

Without a reliable, consistent, and empirically sound means of objectively evaluating scars it is impossible to pursue research that relates objective scar outcomes with the personal experience of a scar. Furthermore, and more practically speaking, it is similarly impossible to provide empiric recommendations on how to optimize postsurgical scarring.

To provide context, this thesis will begin by exploring the contemporary management of skin cancer, as this is the most common means by which an individual might obtain a facial scar. To integrate and understand the impact of facial scarring on an individual's overall wellbeing, facial scarring will be reviewed through the lens of the World Health Organization's International Classification of Functioning, Disability, and Health (ICF) (Stephens, 2001). We will then describe the preliminary validation of a novel scar assessment instrument. Finally, we will strive to integrate the preceding discussions and define potential objectives for future investigation.

## **Chapter 2: Contemporary Management of Non-Melanoma Skin Cancer**

“Non-melanoma skin cancer” represents a broad group of cutaneous malignancies. Included in this category are common Keratinocyte Carcinomas (KC) and rare neoplasms such as Merkel Cell Carcinoma, Adnexal Carcinomas, and Cutaneous Sarcomas. Although divergent in cell lineage and presentation, these malignancies primarily occur in the head and neck region and undoubtedly result in some degree of facial disfigurement and morbidity. Facial plastic surgeons have the unique opportunity to both cure a patient of a potentially life threatening malignancy and also improve their overall quality of life through a well-executed post-ablative reconstruction (Dey, Ishii, Boahene, et al., 2015). This chapter endeavours to provide the reader with a contemporary overview of cutaneous neoplasms that present in the head and neck region.

### **Keratinocyte Carcinomas**

Basal Cell Carcinoma (BCC) and Squamous Cell Carcinoma (SCC) represent the two most common skin malignancies and are frequently lumped together under the umbrella term “Non-Melanoma Skin Cancer”. These two cutaneous malignancies share a cellular lineage with keratinocytes and are thus more accurately termed Keratinocyte Carcinomas (Albert & Weinstock, 2003). As a category, Keratinocyte Carcinomas are the most common malignancies worldwide – with an annual incidence that exceeds all other malignancies combined (Rogers et al., 2015). The incidence of KC continues to grow with well-over 3-million treatments for KC in the United States each year (Rogers et al., 2015). While Keratinocyte Carcinomas are typically well managed and only rarely do they metastasize, these lesions can result in substantial morbidity.

## *Aetiology*

While the risk of developing KC is dependent on genotypic, phenotypic, and environmental factors, it is well-established that ultraviolet (UV) solar radiation is the greatest single risk factor for the development of KC (Madan et al., 2010). UVB (290–320 nm) is considered more carcinogenic than UVA (320–400 nm) as it is completely absorbed in the skin and results in the mutation of tumour suppressor genes (Gailani et al., 1996). UVA which penetrates deeper than UVB also plays a role as it activates the signal transduction molecule protein C- kinase, and also impairs the activity of tumour suppressor T-cells leading to tumour expansion and a failed immune response (Matsui & DeLeo, 1991; Nghiem et al., 2002). Cumulative sun exposure may be more causally related to the development of SCC in that it results in UV-induced DNA damage and subsequent p53 gene mutations (Lee & Miller, 2009; Madan et al., 2010). Mutations of the p53 gene can also be found in up to 50 percent of BCCs (Rubin et al., 2005). In contrast to SCC, intense intermittent recreational sun exposure (i.e., resulting in sun burns) and exposure during childhood may be more central to the development of BCCs (Lee & Miller, 2009; Madan et al., 2010). BCCs frequently demonstrate mutations of chromosome 9q resulting in Patched (PTCH) gene mutations and subsequently induced hedgehog (Hh) signalling (Lee & Miller, 2009). It is this hedgehog signalling pathway that is targeted by the systemic Hh inhibitors Vismodegib and Sonidegib – FDA approved for the treatment of advanced BCC (Chen et al., 2016; Sekulic et al., 2012). Other risks factors for the development of KC appear in Table 2.1.

**Table 2.1:** Risk factors for the development of Keratinocyte Carcinomas\*

<p><b>Risk Factor:</b></p> <ul style="list-style-type: none"><li>UV radiation (sun exposure, tanning beds)</li><li>Ionizing radiation</li><li>Immunosuppression</li><li>Human Papillomavirus</li><li>Smoking</li><li>Chronic scarring / inflammation</li><li>Exposure to polycyclic hydrocarbons</li><li>Phototherapy with psoralens (PUVA therapy)</li><li>Photosensitising drugs (i.e., Fluoroquinolones)</li><li>Arsenic ingestion</li></ul> <p><b>Syndromes:</b></p> <ul style="list-style-type: none"><li>Xeroderma Pigmentosum</li><li>Oculocutaneous albinism</li><li>Nevoid BCC syndrome/Gorlin Syndrome/Basal cell nevus syndrome</li><li>Epidermodysplasia verruciformis</li><li>Dystrophic epidermoylsis bullosa</li><li>Muirre-Torre syndrome</li><li>KID (keratosis, ichthyosis, deafness)</li><li>Fanconi anemia</li><li>Rothmund-Thompson syndrome</li><li>Werner syndrome</li></ul>
---

Note. Risk factors and syndromes that increase the risk of developing Keratinocyte Carcinoma. (\*Adapted from Lee & Miller, 2009 and Madan et al., 2010).

### ***Clinical Features and Work-Up***

Common clinical features of Keratinocyte Carcinomas appear in Table 2.2. Due to the relationship of KCs and UV light exposure, these lesions occur most frequently in the head and neck region. Of the KCs, approximately 75% are BCCs and 25% are SCCs.

**Table 2.2:** *Common Clinical Features of Keratinocyte Carcinomas\**

<p><b>Red Flags:</b></p> <ul style="list-style-type: none"><li>A new rapidly growing lesion</li><li>A lesion that is changing in size or shape</li><li>A non-healing sore</li></ul> <p><b>Nonspecific features that may be seen in Keratinocyte Carcinoma:</b></p> <ul style="list-style-type: none"><li>Nodular growth</li><li>Irregular border</li><li>Elevation</li><li>Erosion, ulceration, crust</li><li>Bleeding</li><li>Erythema with sharp borders</li></ul> <p><b>Features suggestive of Basal Cell Carcinoma:</b></p> <ul style="list-style-type: none"><li>Translucent (pearly or waxy) appearance</li><li>Telangiectasias (fine, tortuous vessels visible near the surface)</li><li>Raised (“rolled”) border</li><li>Pigment without a netlike pattern</li><li>Scar like appearance</li><li>Erythema with pinpoint erosions</li></ul>
---

**Features suggestive of Squamous Cell Carcinoma:**

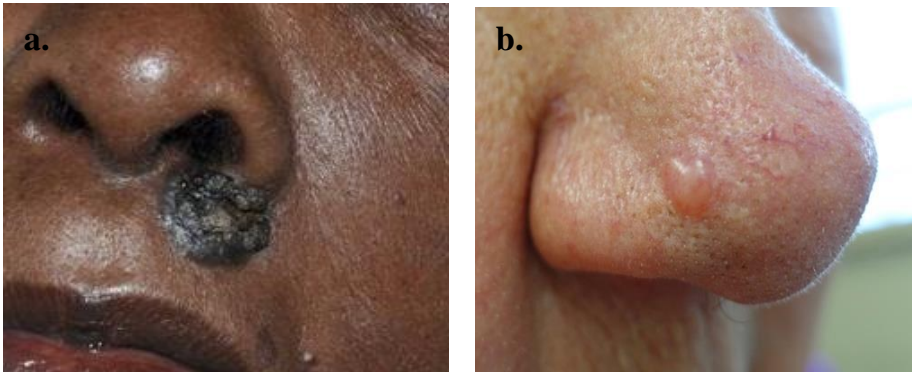
- Adherent scale or crust
- Cutaneous horn
- Extensive erosion of tissue

Note. Common clinical features of Keratinocyte Carcinomas including those that may be more suggestive of BCC and SCC. (\*Adapted from Albert & Weinstock, 2003)

***Basal Cell Carcinoma***

BCCs are clinically categorized as nodular, superficial, and infiltrative or sclerosing subtypes (see Figures 2.1 – 2.7). Nodular BCCs are most common and present as waxy raised papules or nodules with telangiectasias (see Figure 2.1).

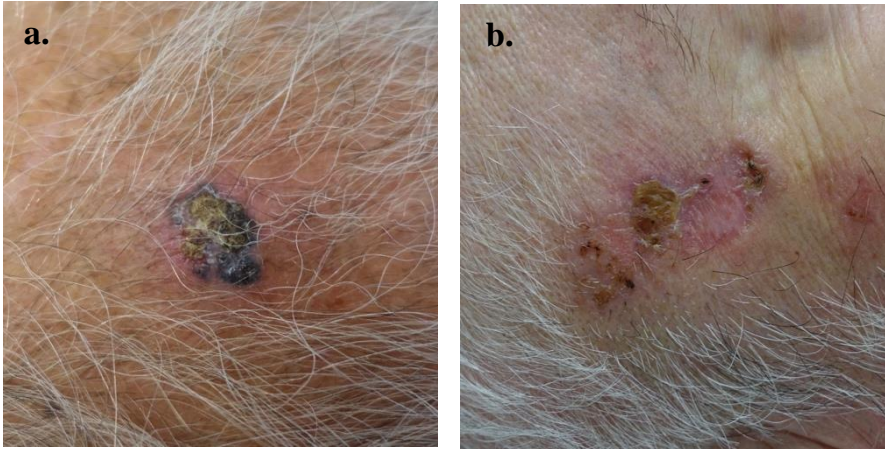
**Figure 2.1:** *Nodular BCCs: Left upper lip nodular pigmented BCC (a) and nodular BCC of the right ala (b).*



Superficial BCCs grow horizontally and present as thin erythematous plaques with variable scale and telangiectasias (see Figure 2.2).

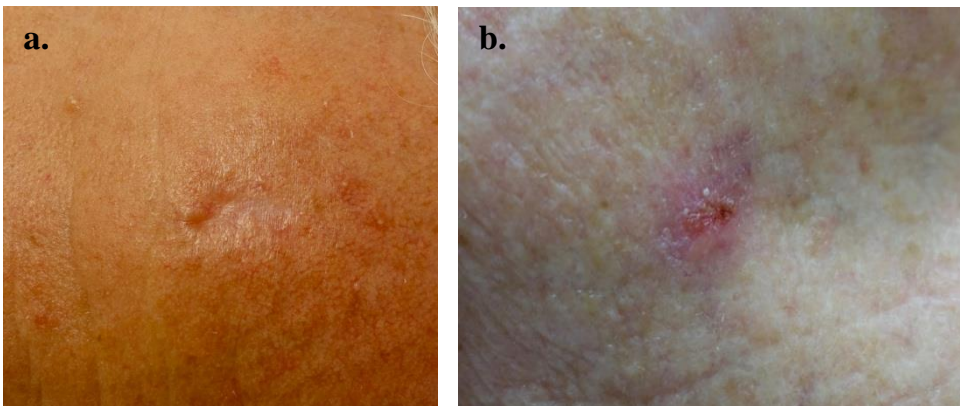


**Figure 2.2:** *Superficial BCCs: Superficial pigmented BCC of the scalp (a) and a large superficial BCC of the right temple (b)*



Sclerosing BCCs are ill-defined, indurated red or white plaques that can be slightly elevated or depressed and atrophic (see Figure 2.3).

**Figure 2.3:** *Sclerosing BCCs: the forehead (a) and the right neck (b)*

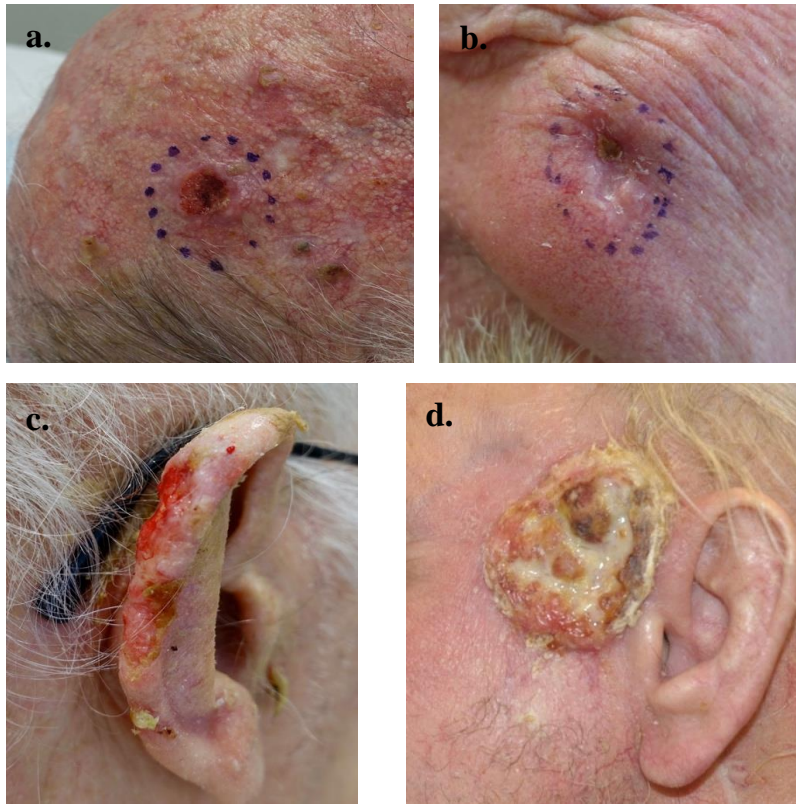



### *Cutaneous Squamous Cell Carcinoma*

Invasive SCC of the skin frequently presents as an erythematous, keratotic papule, plaque, or nodule occurring in a background of actinic damage (see Figure 2.4).

**Figure 2.4:** *Cutaneous SCCs: the scalp (a), the left cheek (b), left ear (c), and left temple/cheek (d).*



These can demonstrate ulceration and patients will often describe a history of an intermittently bleeding and non-healing sore. Actinic Keratosis and Bowen's Disease (SCC in situ) are considered precursor lesions to invasive SCC and frequently present as a well-demarcated erythematous, scaly plaque (Albert & Weinstock, 2003).

## ***Management***

**Biopsy.** Any clinically suspicious lesion should be biopsied. While multiple biopsy techniques have been advocated, a 3 mm full-thickness punch biopsy provides the greatest histologically diagnostic information and is thus recommended for any suspicious lesion. Diagnostic imaging is reserved for clinically aggressive lesions to determine the extent of invasion or to help evaluate for distant metastasis on the basis of clinical suspicion or clinically palpable adenopathy. It is important to recognize that SCC of the lip is considered an oral cancer and accordingly requires clinical and prudent radiographic evaluation of regional lymphatics.

**Resection of the Primary Malignancy.** The primary goal in the treatment of BCC and SCC is to cure the patient of their malignancy while limiting both tumour and iatrogenic morbidity. Further to these goals, the National Comprehensive Cancer Network (NCCN) provides Clinical Practice Guidelines for the evaluation and management of Non-Melanoma Skin Cancers. These guidelines are up-to-date and established by group consensus based on currently available evidence. Guidelines are available at [www.NCCN.org](http://www.NCCN.org) (National Comprehensive Cancer Network [NCCN], 2019a, 2019b).

As the majority of cutaneous malignancies occur in the head and neck region our discussion will focus on cutaneous malignancies arising in this area. The treatment of BCCs and SCCs is guided principally by the risk of local recurrence and/or disease progression. The NCCN indicates that within the head and neck, non-melanoma skin cancers that are most likely to recur present in the central face, are >1 cm in diameter, are clinically poorly defined, recurrent lesions, occur in areas of previous radiation, or

occur amongst patients that are immunosuppressed. In the case of SCC, tumours >6 mm in the central face, rapidly growing tumours, or those that demonstrate neurologic symptoms (i.e., anaesthesia, motor dysfunction) are also considered high-risk (NCCN, 2019a).

For high-risk BCCs and SCCs (with no evidence of metastasis) the NCCN recommends management via Mohs micrographic surgery, resection with complete circumferential margin assessment (i.e., intraoperative frozen section analysis), standard excision with wide margins (4-6 mm) and post-operative margin assessment, or radiation therapy for non-surgical candidates (NCCN, 2019a). For standard surgical excision, Wolf and Zitelli (1987) demonstrated that for well-defined BCCs less than 2 cm in diameter, excision with 4 mm clinical margins resulted in complete removal in more than 95% of cases. Wider surgical margins are recommended for SCCs whereby high-risk SCCs measuring <1 cm, 1-1.9 cm, or >2 cm in diameter require clinical margins of 4, 6, and 9 mm, respectively, when treated via standard surgical excision with post-operative margin assessment (Brodland & Zitelli, 1992).

As per the NCCN guidelines, low-risk BCCs and SCCs can be managed via electrodesiccation and curettage (excluding terminal hair-bearing areas) or via standard excision with 4-6 mm margins and post-operative margin assessment (NCCN, 2019a, 2019b). For non-surgical candidates radiation therapy is recommended.

**Incomplete Excisions and Aggressive Features on Pathology.** Re-excision via Mohs micrographic surgery or resection with complete circumferential margin assessment (i.e., intraoperative frozen section analysis) is recommended for any BCC or SCC that has been incompletely excised in the head and neck region (NCCN, 2019a,

2019b). For those patients that are non-surgical candidates, or amongst those lesions where further surgery is not possible, radiation therapy is recommended (NCCN, 2019a, 2019b). Adjuvant radiation therapy is also recommended for BCCs or SCCs demonstrating perineural or lymphovascular involvement (NCCN, 2019a, 2019b).

**Advanced Disease.** Patients presenting with advanced BCCs or SCCs including those with regional lymphatic involvement benefit from evaluation and management by a multidisciplinary tumour board. NCCN guidelines at [www.NCCN.org](http://www.NCCN.org) provide direction with respect to the management of advanced keratinocyte carcinomas.

The incidence of metastatic BCC ranges from 0.0028 to 0.55 percent. Systemic therapy in the form of Hedgehog (Hh) pathway inhibitors (i.e., Vismodegib, Sonidegib) can be considered amongst any patient presenting with nodal or distant metastatic BCC (NCCN, 2019a). This is also a treatment option for patients with recurrent BCC following resection and adjuvant radiation, or amongst patients who are not candidates for either surgery or radiation (NCCN, 2019a).

Metastatic SCC of the skin occurs with an incidence of approximately 2 to 6 percent (Mokhtar, 2009). The lip and ear represent the sites at highest risk for metastasis in primary SCC with an incidence of 10 to 14 percent (Mokhtar, 2009). It is important to note that recurrent SCC has a 30% incidence of metastasis emphasizing the need for adequate primary control. Neck dissection and adjuvant radiation therapy is recommended for SCCs with regional lymph node involvement and the extent of dissection is dependent on lymph node size, lymph node number, and node location (i.e., parotid, ipsilateral neck, contralateral neck) (NCCN, 2019b). Concurrent systemic

chemotherapy is recommended for any patient demonstrating extracapsular extension of tumour on lymphadenectomy (NCCN, 2019b).

## **Less Common Non-Melanoma Skin Cancers**

### ***Merkel Cell Carcinoma***

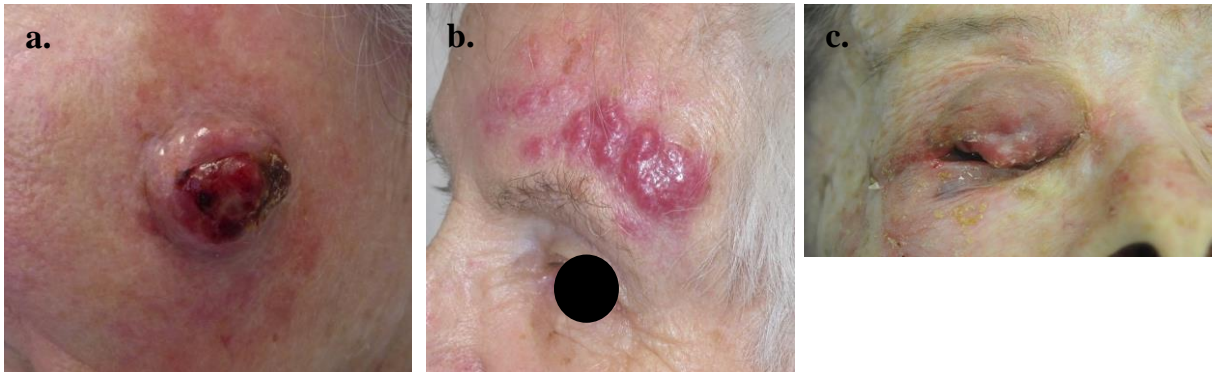
Merkel Cell Carcinoma (MCC) is an uncommon cutaneous neuroendocrine carcinoma. While it remains relatively uncommon, the annual incidence has risen 5-fold over the past 30 years (Tetzlaff & Nagarajan, 2018). In 2011, the incidence in the United States was 7.9 cases per 1 million persons (Tetzlaff & Nagarajan, 2018). MCC primarily affects Caucasian men at sites of chronic sun exposure in their 7<sup>th</sup> to 9<sup>th</sup> decade of life. Immunosuppression is also considered a major risk factor for the development of MCC (Tetzlaff & Nagarajan, 2018). MCC is an aggressive malignancy with a five year survival rate of 50.6% for those with primary disease, 35.4% for those with regional lymph node involvement, and 13.5% for those with distant metastases (Harms et al., 2016).

The cell of origin of MCC is unknown and potentially includes epidermal stem cells, B-cells, and fibroblasts. A novel human polyomavirus named Merkel Cell Polyomavirus (MCPyV) can be detected in 60-80% of Merkel Cell Tumours (Feng et al., 2008). MCPyV works through a variety of mechanisms resulting in inhibited tumour suppressor function and carcinomatous cellular proliferation (Tetzlaff & Nagarajan, 2018).

**Clinical Features and Work-Up.** MCC presents as an asymptomatic, rapidly growing, firm, red, pink, purple, or skin-coloured nodule (see Figures 2.13 – 2.15) (Heath et al., 2008). Heath and colleagues proposed the AEIOU acronym to represent lesions

that are Asymptomatic and Expanding rapidly amongst Immunosuppressed fair skin individuals Older than 50 years at UV-exposed sites (Heath et al., 2008). In spite of awareness of MCC and clinical vigilance its varied appearance results in most MCCs being diagnosed histopathologically on biopsy when differentiated from other small blue cell tumours on positive cytokeratin 20 (CK20) and negative thyroid transcription factor 1 (TTF-1) immunohistochemistry – differentiating it from small cell lung cancer. At time of presentation, 65% of patients present with local disease, 26% of patients present with regional lymph node metastases, and 8% present with distant metastases (Tetzlaff & Nagarajan, 2018).

**Figure 2.5:** *Merkel Cell Carcinomas: the left cheek (a), left forehead (b), and right upper eyelid (c)*



**Management.** Work-up and management is guided by the most up-to-date NCCN guidelines available from [www.NCCN.org](http://www.NCCN.org) (NCCN, 2019c). The authors recommend diagnostic imaging to evaluate for regional lymph node involvement and distant metastasis for any patient diagnosed with MCC. For patients presenting with

clinically palpable lymph nodes, these should be biopsied via fine needle aspiration biopsy (FNAB) or core biopsy. Evaluation by a multidisciplinary tumour board should be strongly considered.

The latest NCCN guidelines recommend sentinel lymph node biopsy (SLNB) prior to definitive surgical excision (NCCN, 2019c). One third of patients presenting with clinically negative lymph nodes are found to have micrometastases on SLNB (Santamaria-Barria et al., 2013). Recurrence occurred in 56% of SLNB-positive and 39% of SLNB-negative patients (Santamaria-Barria et al., 2013). It is important to note that SLNB is less consistent in the head and neck region due to variability in nodal drainage which can result in a false-negative SLNB (Willis & Ridge, 2007). SLNB does however remain useful in guiding the dose and region of adjuvant radiation which is recommended for all patients with MCC except perhaps for those presenting in immunocompetent patients with <1 cm lesions that have been widely excised with no lymphovascular or perineural invasion.

Once SLNB has been performed, the primary tumour requires resection with 1 to 2 cm margins to the investing fascia as recommended by the National Comprehensive Cancer Network (2019c). In the head and neck region this is typically best performed via Mohs surgery, modified Mohs surgery, or complete circumferential peripheral and deep-margin assessment (NCCN, 2019c). Neck dissection should be considered for any patient presenting with regional lymph node involvement diagnosed on FNAB, core biopsy, or SLNB – these patients require evaluation by a multidisciplinary tumour board (NCCN, 2019c). Radiation to the primary site and involved nodal basin is recommended for any patient with nodal involvement (NCCN, 2019c).



Radiation therapy is recommended for the majority of patients presenting with MCC in an adjuvant fashion to the primary tumour site (NCCN, 2019c). For patients with head and neck region MCC, radiation to the nodal basin should be considered even amongst those with negative SLNB due to the aforementioned risk of a false-negative result. These recommendations are based on the NCCN guidelines (2019c) which indicate that adjuvant radiation therapy decreases local recurrence and significantly improves overall survival.

### ***Adnexal Carcinomas of the Skin***

Adnexal carcinomas are rare with an annual incidence of approximately 1 per 20 million persons in the United States (Blake et al., 2010). While rare, the incidence of these tumours has tripled over the past 30 years (Blake et al., 2010). Similar to Merkel Cell Carcinoma, adnexal carcinomas occur most frequently amongst elderly Caucasian males. This category of tumour includes carcinomas of the eccrine and apocrine glands, carcinomas of the hair follicle, and carcinomas of the sebaceous glands. Our review of these lesions will focus on those most frequently affecting the head and neck region and appear summarized in Tables 2.3 – 2.5.



**Table 2.3: Eccrine and Apocrine Gland Carcinomas\***

	<b>Common Site</b>	<b>Gender</b>	<b>Decade</b>	<b>Clinical Features</b>	<b>Keep in Mind</b>	<b>Management</b>
Mucinous carcinoma	Face / Eyelid	F>M	3 <sup>rd</sup> – 8 <sup>th</sup>	Asymptomatic, slow-growing, flesh coloured soft/spongy nodule.	*R/O metastatic mucinous carcinoma from breast or GI tract.	Standard surgical excision or MMS.
Microcystic Adnexal Carcinoma	Face / Upper lip	F>M	6 <sup>th</sup>	Slow growing neoplasm. Indurated firm plaque or discrete nodule. Yellowish to flesh coloured. Epidermal surface is smooth or crusted.	Perineural invasion is common	Standard surgical excision or MMS for the primary tumour. RT +/- Chemotherapy with perineural invasion.
Adenoid cystic carcinoma	Scalp	F>M	5 <sup>th</sup>	Asymptomatic crusted verrucous plaque or deep seated nodule.	Perineural invasion is common	MMS or resection with complete circumferential margin assessment for the primary tumour. RT for perineural invasion.

Acrospiocarcinoma	Face	F>M	>5 <sup>th</sup>	Large , ulcerated mass or nodule or an infiltrative plaque	Frequently metastasize to regional lymph nodes + distant sites	Standard surgical excision + Sentinel node biopsy or neck dissection.
Cylindrocarcinoma	Scalp	F>M	>5 <sup>th</sup>	Typically arise from a pre- existing cylindroma with associated rapid growth, tenderness, ulceration, discoloration and/or bleeding.	Aggressive tumours	Standard surgical excision or MMS for the primary tumour. RT for metastatic disease or inoperable tumours.
Syringocystadenocarcinoma papilliferum	Scalp	M=F	6 <sup>th</sup>	Exophytic verrucous plaque or nodule.	Metastasis is rare.	Standard surgical excision or MMS for the primary tumour.

Key. M= Male, F=Female, RT= Radiation therapy, MMS = Mohs micrographic surgery.

Note. Eccrine and apocrine gland carcinomas (\*Adapted from Walsh & Santa Cruz, 2011) stratified by area of involvement, gender, age at incidence, clinical features, notable features and management.

**Table 2.4: Carcinomas of the Hair Follicle\***

	Common Site	Gender	Decade	Clinical Features	Keep in Mind	Management
Tricholemmoma carcinoma	Head & Neck	M>F	70 <sup>th</sup>	Slow growing papule or nodule.	Metastasis is rare.	Conservative standard surgical excision or MMS
Proliferating/malignant tricholemmal cystic carcinomas	Scalp	F>M	6 <sup>th</sup>	Longstanding subcutaneous mass that has grown rapidly. Firm, painless nodule with overlying alopecia or ulceration.	Aggressive tumours with a high rate of metastasis	Standard surgical excision with wide margins or MMS for the primary tumour. Neck dissection, RT, and chemo has variable to limited success for disseminated tumours.
Matrical carcinoma / Malignant pilomatricoma	Head & Neck	M>F	4 <sup>th</sup>	Slow growing, firm, non-tender nodule. Clinically mistaken as a benign pilomatricoma or inclusion cyst.	Metastasis is common.	Standard surgical excision with 0.5-1cm margins or MMS. RT for metastatic disease or inoperable tumours.

Key. M= Male, F=Female, RT= Radiation therapy, MMS = Mohs micrographic surgery.

Note. Carcinomas of the hair follicle (\*Adapted from Walsh & Santa Cruz, 2011)

stratified by area of involvement, gender, age at incidence, clinical features, notable features and management.

**Table 2.5: Carcinomas of the Sebaceous Glands\***

	Common Site	Gender	Decade	Clinical Features	Keep in Mind	Management
Sebaceous carcinoma	Head & Neck, Eyelid	M>F	70 <sup>th</sup>	Slow growing firm subcutaneous nodule with occasional ulceration. Yellow hue is common at extraocular sites.	Classified as ocular or extraocular. Associated with Muir-Torre Syndrome (especially if diagnosed in younger patients). Can metastasize.	Standard surgical excision with wide margins or MMS for the primary tumour. Sentinel node biopsy may be useful for poorly differentiated and ocular lesions.

Key. M= Male, F=Female, RT= Radiation therapy, MMS = Mohs micrographic surgery.

Note: Carcinomas of the sebaceous glands (\*Adapted from Walsh & Santa Cruz, 2011)

stratified by area of involvement, gender, age at incidence, clinical features, notable features and management.

### ***Sarcomas of the Skin***

Sarcomas of the skin are a broad group of rare non-epithelial primary skin neoplasms. These cutaneous neoplasms are classified according to the mature cell type they resemble. We will focus on three of these neoplasms: the most common sarcoma of the skin – dermatofibrosarcoma protuberans (DFSP), and the most common cutaneous sarcoma of the head and neck - atypical fibroxanthoma (AFX), and the most common vascular sarcoma of the head and neck - cutaneous angiosarcoma (AS) of the face and scalp.

### ***Dermatofibrosarcoma protuberans (DFSP).***

DFSP is the most common sarcoma of the skin. Its annual incidence has been estimated at 4.5 cases per 1 million persons in the United States making DFSP nearly half as common as Merkel Cell Carcinoma (Criscione & Weinstock, 2007). Unlike other rare skin malignancies this tumour most frequently occurs in the 2<sup>nd</sup> to 5<sup>th</sup> decade of life and affects individuals of African American heritage twice as frequently as Caucasians (Criscione & Weinstock, 2007; Rouhani et al., 2008).

DFSP is a low-grade sarcoma of fibroblast origin. DFSP is characterized by a translocation between chromosomes 17 and 22 resulting in the overexpression of platelet-derived growth factor receptor  $\beta$  (McArthur, 2004). It is differentiated from a common dermatofibroma on immunohistochemistry where it is positive for CD34 and negative for factor XIIIa. Given the characteristically slow growth of these lesions, they typically present as large tumours. Microscopically, many deep finger-like projections are present resulting in indistinct borders and recurrence rate as high as 60% (Reinstadler & Sinha, 2012; Stojadinovic et al., 2000). Metastatic disease is uncommon.

**Clinical Features and Work-up.** Dermatofibrosarcoma protuberans typically presents as a slow growing flesh-coloured or pink nodular lesion of the trunk or extremities. Presentation in the head and neck is rare. Over time the tumour develops a more protruberant appearance. The latest NCCN guidelines (2019d) recommend a deep subcutaneous punch or incisional biopsy as superficial biopsies may mistakenly suggest the lesion is a benign dermatofibroma (NCCN, 2019d). Given the low rate of metastasis imaging is not routinely performed. The NCCN suggests MRI imaging if extensive extracutaneous extension is suspected (NCCN, 2019d).

**Management.** Management is directed by the most recent NCCN guidelines available from [www.NCCN.org](http://www.NCCN.org) (NCCN, 2019d). Mohs micrographic surgery or surgical excision down to the level of investing fascia with 2-4 cm peripheral margins is recommended with subsequent complete circumferential margin assessment (i.e., intraoperative frozen section analysis) (NCCN, 2019d). Re-resection is recommended should final pathology demonstrate positive margins (NCCN, 2019d). Given the characteristic microscopic extension of DFSP, undermining and/or flap reconstruction should only be considered once all margins have been histologically cleared (NCCN, 2019d). Radiation therapy and consultation with a multidisciplinary tumour board should be considered amongst patients with recurrent disease or where complete surgical excision is not possible (NCCN,2019d). Chemotherapy can be considered in the rare event of metastatic disease and multidisciplinary tumour board consultation is recommended in this circumstance (NCCN, 2019d).

### ***Atypical Fibroxanthoma***

Atypical fibroxanthoma (AFX) is a very rare low-grade sarcoma of fibroblastic origin. It typically presents in the head and neck region amongst Caucasian males in their 7<sup>th</sup> decade of life (Ang et al., 2009; Reinstadler & Sinha, 2012). Similar to other cutaneous malignancies, AFX presents with increased frequency amongst immunosuppressed patients. As AFX typically occurs in areas of chronic UV exposure, a history of previous keratinocyte carcinomas is common, and frequently the AFX is misdiagnosed clinically as a keratinocyte carcinoma. Due to the rarity of the tumour there is no incidence data (Reinstadler & Sinha, 2012).

Similar to Keratinocyte carcinomas, AFX is believed to arise from UV induced mutations of the p53 tumour suppressor gene (Dei Tos et al., 1994). AFX is histologically similar to other spindle cell neoplasms such as cutaneous malignant fibrous histiocytoma (MFH). The distinction between AFX and MFH has been controversial and in 2002 the World Health Organization recommended the term MFH be replaced by Undifferentiated pleomorphic sarcoma (UPS) – AFX is considered a distinct pathological diagnosis to UPS (Bowles et al., 2011). In contrast to AFX, UPS is considered a diagnosis of exclusion and typically presents as an aggressive subfacial mass of the extremities amongst older adults. UPS is discussed herein as previous reports of aggressive AFX lesions may have been incorrectly categorized and would now be considered UPS.

**Clinical Features and Work-Up.** AFX typically presents as a slow growing ulcerated nodule, and as previously mentioned, clinically resembles keratinocyte carcinoma. On histopathology the lesion is typically confined to the dermis and thus has limited metastatic potential (Bowles et al., 2011). More aggressive features on histopathology raise suspicion that the lesion may be an alternative sarcoma such as UPS. AFX is a diagnosis of exclusion on immunohistochemical analysis and is negative for S100 protein, cytokeratins, and desmin, differentiating it from melanoma, SCC, and leiomyosarcoma (Bowles et al., 2011).

**Management.** Mohs micrographic surgery or surgical excision down to the level of investing fascia with 1-2 cm peripheral margins is recommended with subsequent complete circumferential margin assessment (i.e., intraoperative frozen section analysis). The recurrence rate is approximately 10% for wide local excision and may be lower with

Mohs micrographic surgery (Reinstadler & Sinha, 2012). To reiterate, nodal or distant metastasis do not occur with AFX and these findings suggest a more aggressive soft tissue sarcoma.

### ***Angiosarcomas***

Angiosarcomas are very rare vascular sarcomas that include cutaneous angiosarcoma of the face and scalp. This lesion is considered a high-grade angiosarcoma and most frequently presents at the scalp or forehead amongst Caucasian men in their 7<sup>th</sup> decade of life (Holden et al., 1987). These lesions are highly aggressive and often multicentric with a high metastasis, recurrence, and mortality rate. Prognosis is poor with perhaps 12% of patients surviving five or more years (Holden et al., 1987)h.

Vascular endothelial growth factor (VEGF) is involved in the regulation of endothelial cell proliferation, and VEGF-D levels are significantly elevated amongst patients with cutaneous angiosarcoma of the face and scalp (Mendenhall et al., 2006).

**Clinical Features & Work Up.** Cutaneous angiosarcoma of the face and scalp presents as an ill-defined bruise-like lesion (similar to a hematoma) or as broad facial edema - especially of the eyelids with minimal erythema (Sangeuza & Requena, 2011). Induration and ulceration may occur amongst more advanced lesions with some lesions presenting multifocally (Sangeuza & Requena, 2011).

Tissue sampling can demonstrate immunohistochemical positivity for the endothelial markers CD34 and CD31, as well as, positive vascular endothelial growth factor receptor-3 (VEGFR-3), podoplanin, and the proliferation marker K-67 (Orchard et al., 1996). Tissue biopsies of the periphery of the lesion with testing for the aforementioned immunohistochemical markers can help determine the extent of the



tumour (Sangeuza & Requena, 2011). Given the vascular origin of the tumour and the high propensity for metastasis, imaging of regional lymph nodes and screening for distant metastases is prudent.

**Management.** Ideal treatment involves wide excision of the lesion with subsequent complete circumferential margin assessment (i.e., intraoperative frozen section analysis) and adjuvant radiotherapy (Sangeuza & Requena, 2011). This is frequently not possible due to wide extension at the time of diagnosis. Thus, primary radiation and potentially adjuvant systemic chemotherapy may be the only treatment option. Nevertheless, referral to a multidisciplinary tumour board is recommended.

### **Summary**

Non-melanoma skin cancers are an extensive group of malignancies. The most common malignancy is BCC and is fortunately one of the least aggressive and best managed of the group. The first priority in managing any cutaneous malignancy is ensuring a complete removal with pathologically clear resection margins. This removal will undoubtedly result in a facial defect that requires some form of reconstruction to minimize disfigurement. While some reconstructions result in objectively well-camouflaged scarring, it is the patient's perception of the scar that matters most to their overall wellbeing (Brown et al., 2010). The next chapter will focus on the impact of a facial scar through the lens of the World Health Organization's International Classification of Functioning, Disability, and Health (ICF) (Stephens, 2001).

### **Chapter 3: ICF and Skin Scarring**

The International Classification of Functioning, Disability, and Health (ICF) (Stephens, 2001) is a framework for the cataloguing and description of health conditions and their associated impairments. The ICF strives to integrate the medical model of focusing on an illness or impairment of a bodily structure or function as a medical condition with the more contemporary biopsychosocial model of health (Engel, 1977). By utilizing the biopsychosocial model, it allows for the contextualization of the medical condition and recognizes the unique psychosocial impact and resultant activity limitations/participation restrictions that can occur to a particular individual as a result of the medical condition. For example, focusing medically on a benign facial scar may ignore its potential psychological ramifications and the degree to which it prevents an individual from participating in social activities. The ICF framework strives to provide a more wholistic lens from which we can better understand the true impact of a health condition. While this framework succeeds in describing many health conditions, it is not without its own limitations. To this author's knowledge, no previous investigations have utilized the ICF framework for describing the health condition or functional impairments of skin scarring (i.e., congenital, post-traumatic, or postsurgical scarring). The goals of this chapter are to explore the current application of the ICF model to skin scarring, highlight previous investigations that apply the principles of ICF framework to skin scarring, and define areas for future investigation.

#### **Skin Scarring through the ICF model**

The ICF describes skin scarring as an impairment in the “repair functions of the skin” (b820) – “Functions of the skin for repairing breaks and other damage to the skin”

(Stephens, 2001). This description highlights physiologic dysfunctions of scar formation – i.e., the “functions of scab formation, healing, scarring; bruising and keloid formation” (Stephens, 2001). This description captures the underlying impairment in body function (dysfunction in skin healing physiology) that produces most clinically obvious scars (i.e., overabundant wound healing resulting in an overgrown/hypertrophic/keloid scar). Where this description falls short is in classifying clinically obvious scars resulting from “normal” wound healing physiology (i.e., a poorly placed/obvious scar, a scar with uneven texture, a scar with visible surgical markings/suture marks, etc.). To this end, the ICF applies the body structure classification whereby the “skin of the head and neck” can be identified to have a structural impairment (s8100) (Stephens, 2001). Thus, the ICF model can define the health condition of an obvious scar as an impairment of body function (i.e., a scar resulting from dysfunctional physiology) or simply based on its presence and subsequent structural impairment of the head and neck region.

Although the ICF succeeds at identifying the presence or absence of an impairment in body structure or function, it is limited in its ability to stratify these impairments with respect to severity. Current qualifiers within the ICF stratify impairments in body structure or function as being “no, mild, moderate, severe, or complete” problem(s) (Stephens, 2001). This certainly applies in some circumstances (i.e., complete impairment in this use of one’s left hand), but is limited in its ability to accurately convey more subtle impairments (i.e., a slightly obvious 2cm forehead scar). The degree to which an impairment exists undoubtedly influences the extent to which it causes an activity limitation and/or participation restriction. Thus, the ability to

accurately stratify the degree of impairment is paramount to effective clinician communication and outcomes research.

### **Contemporary Objective Scar Evaluation**

The scar literature presents numerous methods for objectively evaluating skin scarring. Briefly, current scar evaluation scales include: the Vancouver Scar Scale (Baryza & Baryza, 1995), Patient and Observer Scar Scale (Draaijers et al., 2004), Manchester Scar Scale (Beausang et al., 1998), Stony Brook Scar Evaluation Scale (Singer et al., 2007) and the SCAR Scale (Kantor, 2016). Although these scales generally demonstrate excellent reliability, they force the evaluation of scar dimensions (i.e., scar colouration) into categories (i.e., normal, pink, red, purple), or along a linear equal-appearing interval ordinal scale (i.e., 0 to 10). While categorical and linear scaling may be appropriate for particular scar features, they fail to allow for scaling minor scar differences – for example how would one categorically scale a scar that is normal with some pink components. These scales also fail to quantify abstract features – for example, it would be challenging to apply a numeric scale indicating the degree to which a scar might distort surrounding facial structures. Additionally, particular scar variables (i.e., vascularity and pigmentation) have been empirically shown to conform to curvilinear mathematical models (Brandt et al., 2009), and thus the use of linear ordinal scaling measures for these variables do not conform to their inherent mathematical assumptions. Thus, although categorical and ordinal scar evaluation scales may be reliable, they are inherently insensitive to minor scar differences, have difficulty quantifying some features, and struggle with mathematical assumptions that may not apply to all scar variables. These issues consequently impede the ability to classify skin

scars and also impair the use of these scales in clinician communications or scar outcomes research.

### **Visual Analog Scaling**

To overcome some of the limitations of current scar evaluation scales, several attempts have been made to utilize visual analog scaling (Beausang et al., 1998; Singer et al., 2007). Visual analog scaling employs a line of set length (i.e., 100 mm), and asks observers to mark where they feel a particular scalable feature falls on that line. This technique does not require conformity to a particular mathematical model and has been previously applied in the voice assessment literature in the characterization of abstract voice dimensions such as voice “pleasantness” (Eadie & Doyle, 2005). Both the Manchester Scar Scale (MSS) and the Stony Brook Scar Evaluation Scale (SBSES) draw on this scaling technique as a means of obtaining a gestalt summary score for the overall appearance of a scar (Beausang et al., 1998; Singer et al., 2007). While the utility of this method of assessing overall scar appearance cannot be discounted, both the MSS and SBSES also employ additional ordinal and/or categorical scaling for independent scar features (i.e., colour, height, width, distortion, texture, etc.) (Beausang et al., 1998; Singer et al., 2007). In striving to achieve a valid method of scar severity classification, independent scar features and overall gestalt measures require the use of reliable and methodologically valid measurement techniques. Thus, there remains a need for the development of an instrument that can be employed for the universal, valid, and reliable classification of skin scar severity.

## **The Patient's Perspective**

In addition to the aforementioned limitations of clinical scar outcome/assessment measures, few scar scales include the patient's own perspective on their scar (Durani et al., 2009; Idriss & Maibach, 2009). As described earlier, the limitations and restrictions posed by a scar are based primarily on the individual's self-perceived severity of their scar (Brown et al., 2010). A recently developed patient reported outcome (PRO) instrument – the SCAR-Q – has been validated by Klassen and colleagues (2018) to address this limitation (Klassen et al., 2018). This tool will help further elucidate the patient specific outcomes that can be combined with objective scar assessment to yield a more comprehensive understanding of scar severity and its biopsychosocial impact.

## **Social Impairment**

Notwithstanding the importance of defining the severity of impairment in body structure and/or function, the ICF seeks to determine the resultant activity limitations and/or participation restrictions caused by this impairment. To this end, contemporary research has largely focused on defining the impact of facial scarring on social interactions (Kapp-Simon, 1986; Pillemer & Cook, 1989; Pope & Ward, 1997; Rumsey et al., 2004), quality of life (Bock et al., 2006) and psychological well-being (Brown et al., 2010; Love et al., 1987; Malt & Ugland, 1989; Ramstad et al., 1995; Rumsey et al., 2004; Sobanko et al., 2015; Tebble et al., 2006). The majority of this research focuses on children and adolescents with congenital craniofacial abnormalities resulting in facial disfigurement (i.e., Tessier clefting, cleft lip, facial abnormalities associated with syndromes, etc.) (Kapp-Simon, 1986; Okkerse et al., 2001; Pope & Ward, 1997; Tessier, 1976) with only a few investigations highlighting acquired facial scarring (i.e., due to

burns, trauma, or surgical/operative scarring) (Borah & Rankin, 2010; Brown et al., 2008; Ishii et al., 2009; Kim et al., 2013; Rankin & Borah, 2003; Sobanko et al., 2015; Tebble et al., 2006; Van Den Elzen et al., 2012). While much of the literature succeeds at suggesting the impact of facial scarring, to this author's knowledge none have addressed this impact utilizing the framework set-forth by the ICF (Stephens, 2001). Further, very few investigations have specifically inquired into the activity limitations and participation restrictions of those with facial scarring beyond a superficial discussion of social and/or vocational activities (Sobanko et al., 2015).

### **Summary: The Need for a Biopsychosocial Lens**

Skin scarring as a health condition identifies flaws in the medical model of health as this model focuses primarily on diagnosis and treatment and does not conceptualize the impact of the health condition on the particular individual. As a corollary, scar evaluation scales have also primarily focused on individual scar features with very few attempts at evaluating the psychological and social impact of a scar on the affected individual. The biopsychosocial model of health strives to integrate the health condition into an individual's unique psychological and social context. For example, a very visible facial scar in North America may be viewed as undesirable, depressing, socially isolating and in need of treatment, whereas the same scar in tribal Africa may be viewed favorably and as a sign of higher social status. Thus, the biopsychosocial model of health works to contextualize the health condition for a particular individual. It is this biopsychosocial model on which the ICF framework is built with the goal of providing a means for reviewing health conditions and their associated impairments, activity limitations, and

participation restrictions. The ICF model thus provides the necessary means for a more comprehensive understanding of the impact of skin scars.

The very first step in the process of applying the ICF model and understanding the psychological and social impacts of a scar requires an accurate and consistent means of evaluating skin scars. Given the previously reviewed limitations of current scar evaluation scales, the development of a valid scar assessment tool is necessary. Only through the development of such a tool can the patient reported outcomes and psychological and social impact be truly understood. Thus, the development of a novel valid scar evaluation scale is the focus of the next chapter.



## **Chapter 4: Preliminary Reliability Analysis of a Novel Scale for the Objective Evaluation of Linear Scars**

### **Introduction**

Surgeons have long sought methods of achieving optimal post-operative surgical scars. In spite of these efforts, no objective data exists to support scar optimization techniques. A longstanding challenge in establishing scar optimization techniques centers on the ability to objectively evaluate scars. While several scar evaluation scales have been proposed (Baryza & Baryza, 1995; Beausang et al., 1998; Draaijers et al., 2004; Kantor, 2016; Sullivan et al., 1990; Vercelli et al., 2003), they largely have been limited by the inconsistent application of the scales, or incorrect assumptions about how scar dimensions (e.g., pigmentation, vascularity, pliability, etc.) can be assessed relative to the inherent mathematical limitations of the scar scales themselves (Brandt et al., 2009).

### ***Literature Review and Critical Appraisal***

Several publications have summarized contemporary strategies for assessing postsurgical scars and current scar rating scales (Durani et al., 2009; Idriss & Maibach, 2009; Perry et al., 2010; Roques & Téot, 2007; Vercelli et al., 2003). Briefly, current scar evaluation scales including the Vancouver Scar Scale, Patient and Observer Scar Scale, Manchester Scar Scale, Stony Brook Scar Evaluation Scale, and SCAR scale primarily utilize categorical and/or ordinal scaling methods. Although these scales demonstrate good-to-excellent between-rater and within-rater reliability, they force the evaluation of specific scar dimensions (i.e., pigmentation) into categories (e.g., normal, pink, red, purple), or characterization using a linear, equal-appearing interval ordinal scale (i.e., 1 to 10). While categorical and linear scaling may be appropriate for particular

scar dimensions, they fail to allow for scaling minor scar differences across the full spectrum of scar severity. Furthermore, particular scar variables (i.e., vascularity and pigmentation) have been empirically shown to conform to curvilinear mathematical models (Brandt et al., 2009) and, thus, the use of linear, equal-appearing interval scaling measures for these variables does not conform to their inherent mathematical assumptions. Thus, although categorical and ordinal scar evaluation scales may be reliable, they tend to be insensitive to minor scar differences and are inconsistent with mathematical assumptions that may not apply to all scar dimensions.

To overcome the limitations of categorical and ordinal scar scaling, several attempts have been made to utilize visual analog scaling (Duncan et al., 2006; Singer et al., 2007). Visual analog scaling employs a line of set length (i.e., 100mm), and asks observers to mark where they feel a particular scalable dimension falls on that line; absolute anchors for a given scale are provided, but in contrast to equal-appearing-interval scales, no intrinsic value is provided to the rater. Both the Manchester Scar Scale (MSS) and the Stony Brook Scar Evaluation Scale (SBSES) draw on this scaling technique as a means of obtaining a gestalt summary score for the overall appearance of a scar. While the utility of this method of assessing overall scar appearance cannot be discounted, both the MSS and SBSES employ additional ordinal and/or categorical scaling for independent scar dimensions (i.e., colour, height, width, distortion, texture, etc.). In striving to define methods to improve surgical scarring, one must employ a scar evaluation scale that evaluates overall scar appearance but also allows for the accurate evaluation of independent scar features. As particular scar improvement strategies may alter unique scar dimensions independently, a valid and practical scar evaluation scale

must allow for the measurement of each independent variable so that one may be able to establish the degree that each variable plays in the overall, composite appearance of a scar. Additionally, it is possible that a given dimension of a scar may carry considerably greater impact relative to another dimension. Thus, the ability to measure specific dimensions inherent in a scar, while at the same time assessing the global characteristic of a scar may provide valuable clinical information on treatment change and efficacy.

### ***Objectives***

This investigation sought to build on the limitations of contemporary scar evaluation scales and generate a scar scale that could be utilized for the valid and reliable evaluation of independent scar dimensions, as well as, serving to document overall scar acceptability.

### **Methods**

#### ***Participants***

Thirty-four adults (25 women, 9 men) ranging in age from 19 to 63 years (Mean: 30 +/-1 year) served as scar observers/evaluator participants. These participant observers were voluntarily recruited from a population of university students and hospital employees (i.e., secretaries, therapists, service staff, etc.) who were naïve relative to any formal exposure to scars or the methods used to evaluate them. The participant observers included those without personal experience with surgical scarring to avoid any undue influence of personal bias in evaluating surgical scars as part of this project. Scar observers were asked to participate in a prospective, randomized evaluation of surgical scars using the novel scar scale software. Research ethics approval was obtained

(HSREB# 12501E) and informed consent was obtained from all participant observers prior to their participation.

### *Sample size calculation*

To achieve meaningful inter-rater and intra-rater assessments, sample size calculation required a minimum of 23 subjects. That is, a total sample size (N) of 23 individuals was determined to be sufficient to detect the hypothesized effect ( $r^2=.12$ ) of within-subject independent variable 81.6 percent of the time using a .05 alpha level, assuming a within-subject correlation of .30 (Lee, 2014). This sample size was exceeded during the study.

### *Design*

This investigation was designed as a three-phase study. The first phase involved the design and development of a novel scar assessment instrument. To allow for automated pilot testing, the second phase involved the development of a novel computer-based scar evaluation program. The third phase then utilized this novel software to allow for a prospective and randomized assessment of the novel scale's reliability and validity.

**Phase 1: Scale Development.** A review by Durani et al. (2009) thoroughly discusses current scar scales and makes strong recommendations for the generation of a novel assessment instrument, including the rigorous methodology required to generate such an instrument (Durani et al., 2009). Based largely on these recommendations, the present investigation sought to generate a reliable and valid scar assessment instrument.

The first component of generating a useful scar scale requires the establishment of the dimensions to be scaled. Such features as the length, width and height of a scar are reasonable to consider, but these do not provide a complete description of all scar features

which could also include the colour of a scar, any evidence of surgery (i.e., suture marks), distortion of surrounding structures (i.e., the eyelid is pulled by a temple scar), etc. To this end, we reviewed the literature and all contemporary scar assessment instruments in an effort to better understand the dimensions central to scar evaluation (Baryza & Baryza, 1995; Beausang et al., 1998; Draaijers et al., 2004; Kantor, 2016; Sullivan et al., 1990; Vercelli et al., 2003). This review established that only scar pigmentation (i.e., the colour of a scar) was universally scaled. Additional quantifiable physical dimensions and qualitative subjective dimensions were also included in these instruments, but there was no consensus across these assessment instruments as to which dimensions provide the most descriptive information. Given this lack of uniformity, we turned to patients and experts to further elucidate a reliable list of dimensions central to scar characterization and evaluation.

Fifty structured qualitative patient interviews took place whereby individuals with a scar on the face or neck were asked about their scar and the dimensions they felt most accurately described it. The patient population included any individual presenting to a tertiary-care skin cancer clinic for post-operative evaluation of a facial reconstructive procedure resulting in a facial scar (i.e., Mohs closure, scar revision, etc.). Each patient was invited to voluntarily participate in this short interview. Patients were excluded from participation if English was not their primary language. All interviews were conducted independently by the primary author (MGB), whereby the author presented the purpose of the study and asked patients to comment on the key features that characterized their scar. A list of critical, patient generated, dimensions were subsequently generated.

Following the determination of dimensions deemed to be important to patients, experts were next asked to comment on the dimensions they felt were important to skin scar evaluation. A structured interview of eight Board Certified Otolaryngologist – Head and Neck Surgeons (varying in experience from five to twenty-five years), and ten clinical nurses (varying in experience from one to fifteen years), took place. These interviews were conducted independently by the primary author (MGB). Each interviewee was shown a series of linear scars of the face or neck varying in general severity and then asked to comment on the dimensions they felt were most important to characterize these scars. This process generated a list of scar dimensions that were expert-critical.

Next, the investigative team (MGB, CCM, PD) reviewed the patient-critical and expert-critical scar dimensions. Each dimension was independently assessed for its relevance, clarity, and validity to the goal of the scar assessment instrument. This generated a core group of dimensions. Synonymous and similar terms for specific dimensions (i.e., pigmentation, colouration) were combined and the final wording of the dimensions to be scaled were then formulated. It is important to recognize that while individual dimensions were formulated, they were not mutually exclusive which speaks to the complexity of scar scaling. Nevertheless, this process resulted in a set of eight observer scalable dimensions (see Table 4.1). Of the eight dimensions, five were similar to those appearing in previously reported scales – Height, Width, Pliability, Irregularity and Distortion (Kantor, 2016; Vercelli et al., 2003), taxonomy was change for one dimension – Discolouration, and two were unique to this investigation –Evidence of Surgery, and Camouflage. The descriptors/prompts for each dimension were generated

and agreed upon by the research team. These dimensions were then submitted to an assessment of their face validity.

**Table 4.1:** *Dimensions assessed in the Scar Scale*

<u>Dimension</u>	<u>Description</u>
Width	How thick is the scar?
Height	How raised is the scar?
Discolouration	How much does the colour vary from normal adjacent tissue?
Pliability	How pliable does the scar appear if moved between your fingers?
Irregularity	How even is the scar along its course (i.e., bumpy, rough, etc.)?
Distortion	How distorted is the skin adjacent to the scar?
Evidence of Surgery	Are there any features that make the scar appear operated on? (i.e., suture marks, drain marks)?
Camouflage	How obvious is the scar?

Note. Scar Scale Dimension definitions. This list was provided to all scar observers during their assessments.

Face validity assessment asked a group of 30 volunteer participants (non-medical professionals varying in age from 23 – 64 years) and who were naïve to the goals of this investigation what each dimension and descriptor meant to them. Through this process, the dimensions and prompts were then refined to those appearing in Table 4.1.

Once the set of dimensions for scar evaluation were generated, we reviewed the literature for the best means of scaling these dimensions. Contemporary scales were

found to utilize descriptor based categorical scaling, ordinal linear scaling, or visual analog scaling. Descriptor based categorical scaling requires the scar evaluator to select the best choice from a group of predetermined, potential options (i.e., the colour of the scar is: 1 - Red, 2 - Pink, 3 - Blue, etc.). This type of scaling is impractical to a useful scar assessment instrument as it does not afford a means of grading dimensions (i.e., the colour of the scar sits somewhere between pink and red and has a bluish tinge). Given this important limitation, no descriptor based categorical scaling was utilized within our assessment scale.

In contrast to descriptor scaling, linear ordinal scaling is a means of evaluating a dimension whereby an evaluator ranks the dimension using a predetermined, equal-appearing interval scale (i.e., the redness of the scar is graded 2 out of 10). Typically, such scales are constructed so that one end of the scale (e.g., “1”) is normal which the opposite end of the scale (e.g., “10”) represents the most extreme descriptor for a given dimension. The inherent limitation of utilizing a linear scale is whether the dimension being measured conforms to the mathematical assumptions of linear scaling. For example, the dimension of length can be linearly scaled (i.e., the scar is 2 cm vs. 1 cm long). A challenge occurs when one attempts to assign a linear value to a dimension that does not grow in a linear fashion (i.e., how much more pigmented is scar A compared to scar B)? Using this example, a scaled score of 4 cannot be assumed to be half as pigmented as that of one that is scaled as a 2. The underlying issue in this situation is that while some dimensions logically grow linearly (e.g., length), many are characterized by increasing changes that cannot be captured using the linear assumptions that exist for equal-appearing-interval scales. This question was the basis of a previous investigation



by our group whereby it was experimentally determined that some dimensions do not conform to the assumptions of linear scaling (Brandt et al., 2009). Thus, a linear equal appearing interval scale was not utilized for the creation of our novel scar assessment instrument.

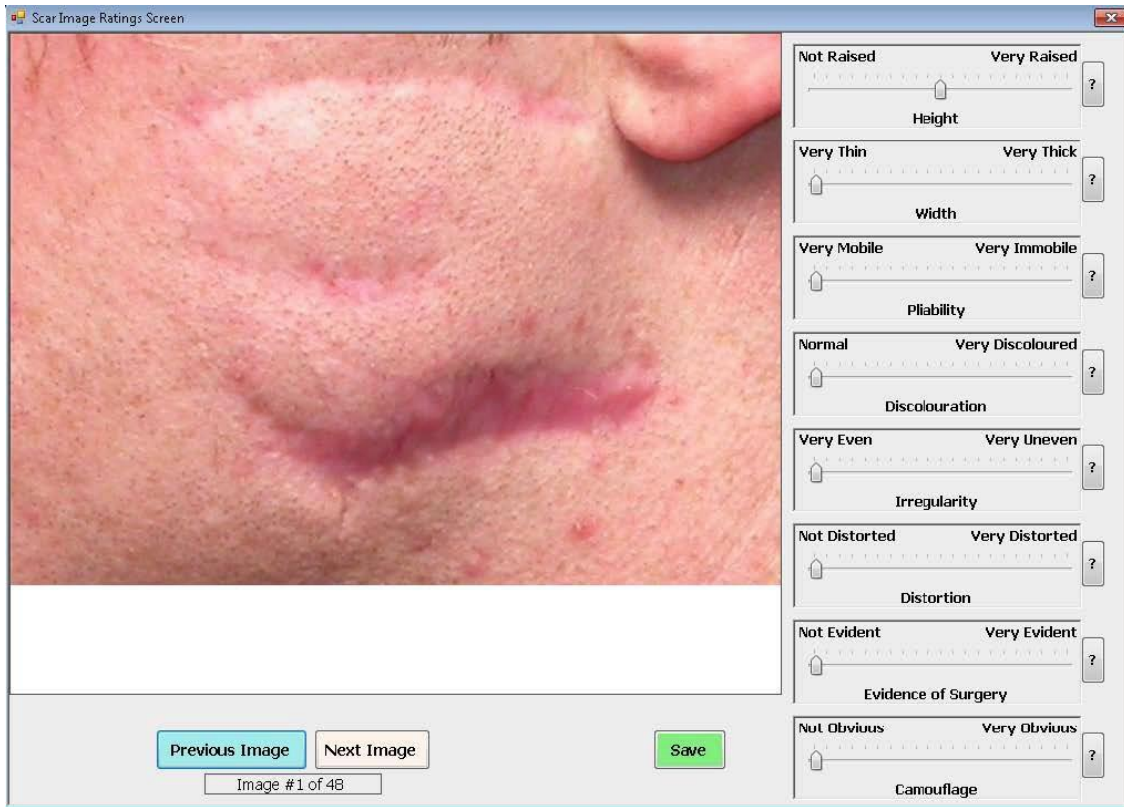
Relative to categorical or equal-appearing interval methods of measurement, visual analog scaling requires an evaluator to mark where they feel the item being measured falls along the full spectrum of a specific dimension – visually represented as a line of set length between two anchor points. To adequately scale a dimension, the anchor points must represent extremes for the dimension. For example, an evaluator would evaluate a scar for how red it appears and then mark a point along a 10 cm line whereby one anchor point/end of the line indicates “no redness” and the other anchor point indicates “extremely red”. The infinite choices provided by this visual representation of the gradient of the scale (the line) provide a means of scaling with no inherent limitations as to the type of dimension being scaled (i.e., whether the dimension is linearly quantifiable). The most significant advantage of using VA scaling methods for assessment of subjective dimensions is that it is appropriate for both those types of scaled continua that grow linearly as well as those that do not. Thus, VA scaling provides an ideal means of gathering valid measures of dimensions such as those which characterize surgical scars. This type of scaling has been successfully applied to the voice perception literature to evaluate subjective and abstract voice dimensions such as pleasantness or harshness (Eadie & Doyle, 2002a, 2002b). Given the success found in utilizing this form of scaling in evaluating abstract dimensions within other areas, the application of a visual analog scale to the realm of scar assessment is a logical and empirically supported

progression. As such, two contemporary scar evaluation scales utilize this as a gestalt summary measure of overall scar appearance with excellent reliability (Duncan et al., 2006; Singer et al., 2007). Given the utility of visual analog scaling and its application to the evaluation of subjective difficult to scale dimensions, visual analog scaling was chosen as the method of dimension scaling for our scar evaluation instrument.

**Phase 2: Scar Evaluation Automation.** To evaluate dimensions scaled using a visual analog scale, one typically measures the location of the evaluators marking along the defined length of the visual analog line (i.e., the evaluator puts a pen mark for “redness” at a point 7 cm along a 10 cm line, resulting in the score of 7 for that dimension). If we measured the visual analog ranking of 8 dimensions across 48 scar photographs, this would require 354 ruler measurements per subject. The application of this form of scaling would thus render itself impractical for the validation of a scar assessment instrument requiring a large volume of participants. To meet this challenge, we recruited the assistance of Dr. Vijay Parsa, School of Communication Sciences and Disorders, Western University, Canada to facilitate the development of a computer-based software application (Scar Ratings Software (ScaRS)).

The ScaRS program displays a random photo of a scar and a set of preselected, but randomly organized dimensions, each with their corresponding gradient lines (see Figure 4.1). A moveable tab along the gradient line allows participants to scale the dimension in a visual analog fashion. When all dimensions have been scaled, the subject can move forward to the next randomly selected photo. Once all photos have been evaluated, the software reorganizes the images and their resultant dimension scores so that they can be conveniently tabulated in a spreadsheet.

**Figure 4.1:** *ScARS - Scar Rating Software*



Note. Screenshot of the ScARS program developed by Dr. Vijay Parsa, PhD, Western University, Canada. Scalable dimensions appear on the right. A slider allows the visual-analog scaling of each dimension. The question mark appearing to the right of each dimension provides a written explanation of the dimension being scaled.

**Phase 3: Scar Evaluation.** With a novel scar assessment scale, dimensions identified and defined, and a software program developed, this investigation sought to determine the reliability, validity, responsiveness, interpretability, and feasibility for use of the scale within a clinical environment. To this end, a prospective and randomized evaluation took place.

## ***Procedure***

Participants were asked to evaluate 40 high-resolution photos of surgical scars. These were obtained from a database of patient photographs. All patients consented to the storage of their photos and the use of these photos for ethics approved research. The photos were cropped and magnified to demonstrate the scar in its entirety. Any concealer make-up was removed prior to scar photography. The scars varied by location, size, shape, color, and presumed texture. Scars were located on the forehead, cheek, upper lip, lower lip, chin, upper neck, and lower neck, and varied in length from 3 cm to 10 cm. To ensure ratings were consistent and reliable, eight of the scar images - varying in severity (determined through a group consensus exercise), were selected as repeat images to be evaluated twice, resulting in a total set of 48 images. None of the photographs represented “area” scars; rather, all scars were linear and the result of incisions of varied length.

For each scar photo, participants were asked to rate the scar across the dimensions of Height, Width, Discolouration, Pliability, Irregularity, Distortion, Evidence of Surgery, and Camouflage using the visual analog scale. Participants were provided with a description of each scar dimension through the testing software. All testing was performed independently using the novel ScaRS program. Both the order of photo presentation and the list of scalable dimensions were randomized for each participant. Observers were allowed to take as much time as necessary to view the photographs and provide their ratings and were additionally allowed to alter their evaluations throughout the test. All assessments were conducted in a quiet laboratory used for psychophysical research and all images were presented via a desktop computer (Sony Vaio) and high-

resolution color monitor (Samsung MultiSync 1700). Once testing had begun, participants were not allowed to ask questions of the research team. At the completion of testing, participants were allowed to ask questions and provide comments to the research team.

### ***Outcome Measures and Statistical Analysis***

All data analyses were performed using PSAWStatistics 18 (IBM, Minneapolis, MN). Ratings across observers for each scar photograph were pooled to allow for a determination of the mean and variability of responses. This was done to ensure that the scaling procedure could evaluate and capture a wide range of scar severity.

Cronbach's alpha coefficient is widely understood to indirectly indicate the degree to which a set of items measures a single unidimensional construct. Thus, Cronbach's alpha was used to evaluate between-rater/inter-rater agreement across each scar scale dimension for each individual photo. For the eight scar photos with repeat evaluations, Cronbach's alpha scores were also utilized to determine within-rater/intra-rater agreement for each scar dimension.

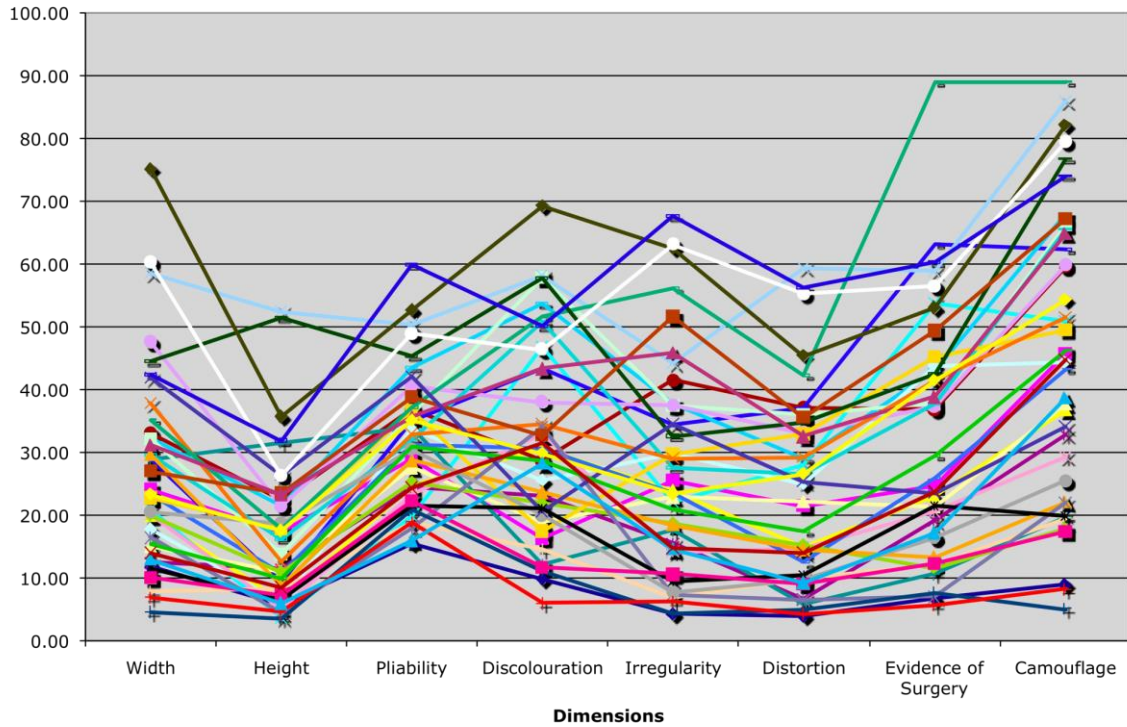
To better understand the influence of using this novel testing software and to determine the role of familiarity with the use of a visual analog scale, a second data set was generated whereby the ratings for first two images evaluated by each observer were eliminated from the data set – as the photographs were presented in random order, the eliminated ratings were ultimately removed in a randomized fashion. This data set provided data free of any learning bias and was subsequently compared to the original data set that included the ratings for all the images.

## Results

All participants completed the evaluation task and required approximately 43 +/- 3 minutes (Mean +/- Standard Deviation) to complete the ratings for 48 photos (inclusive of the 8 repeat images). Thus, a total of 13,056 independent ratings were gathered [(# photos) x (# viewers) x (# dimensions)].

Figure 4.2 graphically demonstrates the mean rating for each of the scar photos across the dimensions evaluated. This figure illustrates that the scar photographs demonstrated variability in the severity of the dimensions evaluated. Table 4.2 presents the overall mean ratings of the scar photos for the dimensions evaluated. This table illustrates the range of scar severity across the eight dimensions being evaluated. Figure 4.2 and Table 4.2 demonstrate variability of severity amongst the scar photos and the utilization of the full spectrum of the visual analog scale by the observers.

**Figure 4.2:** Mean Scar Photo Ratings



Note. Mean rating for each dimension for each scar photo. Coloured dots represents the mean ratings for each scar photo for the corresponding dimension. Possible responses range from 0 to 100 for each dimension. Variation in dimension ratings represents the spectrum of severity for each dimension across the forty-image data set.

**Table 4.2:** Scar Photo Range of Responses

	Width	Height	Pliability	Discolouration	Irregularity	Distortion	Evidence of Surgery	Camouflage
<b>Mean</b>	23.88	15.28	33.17	34.88	26.46	24.02	30.58	45.30
<b>Min</b>	3.62	3.42	13.73	5.71	3.78	3.76	5.26	4.38
<b>Max</b>	75.52	53.03	57.76	73.88	68.03	64.97	92.67	88.60
<b>95% CI</b>	18.78; 28.98	11.64; 18.93	29.78; 36.55	29.42; 40.35	21.41; 31.52	19.15; 28.89	24.38; 36.78	38.08; 52.52

Note. Range of responses for the overall image data set. Values presented as mean rating for all images across each of the scaled scar dimensions. Minimum, Maximum, and 95% Confidence Interval (CI) data is presented. Possible responses range from 0 to 100 millimeters for each dimension. Variation in responses represents spectrum of severity for each dimension across the forty-image data set.

Within-rater / intra-rater agreement across the 8 repeated photos is presented in Table 4.3. These are presented as Cronbach's alpha coefficients across the 8 repeated photographs.

**Table 4.3:** Within-rater agreement for the eight scaled dimensions

<u>Scar Dimensions</u>	<u>Intra-rater Agreement</u>
Width	0.788
Height	0.818
Pliability	0.837
Discoloration	0.744
Irregularity	0.764



Distortion	0.796
Evidence of Surgery	0.925
Camouflage	0.878

Note. Intra-rater agreements for the eight scalable dimensions presented as Cronbach's alpha coefficients.

Table 4.4 provides the between-rater / inter-rater reliability for the 8 scaled dimensions across the entire set of 40 photos. These are also presented as Cronbach's alpha coefficients.

**Table 4.4:** *Between-rater agreement for the eight scaled dimensions*

<u>Scar Dimensions</u>	<u>Inter-rater Agreement</u>
Width	0.903
Height	0.898
Pliability	0.904
Discoloration	0.913
Irregularity	0.777
Distortion	0.937
Evidence of Surgery	0.963
Camouflage	0.939

Note. Inter-rater agreements for the eight scalable dimensions presented as Cronbach's alpha coefficients.

The original data set was compared to the data set, whereby the first two ratings were removed (i.e., for the 40 scar photos randomly presented, the first and second photo data were removed) thus, providing ratings for only 38 photos. This data was evaluated to

determine whether unfamiliarity with a visual-analog scale influenced the ratings of scars across the eight scalable dimensions. Mean ratings for the 8 scalable dimensions for the 40 presented photographs did not vary significantly when the two data sets were compared.

## **Discussion**

The goals of this investigation included the determination of a core set of scalable dimensions for the characterization of linear scars, the development of a novel scar evaluation scale, and the testing of a scar evaluation computer program.

Through rigorous methodology, a core set of scar dimensions were established (Table 4.1). These dimensions were derived through previously validated contemporary scales, interview consensus, and face validity testing. The majority of dimensions demonstrated strong between-rater (Table 4.4) and within-rater (Table 4.3) agreement amongst a set of 34 participants. Based on these results, it appears that the dimensions assessed can be scaled in a reliable fashion. While differences in the degree of consistency did vary by dimension, which is to be expected, overall, raters assessed each dimension with what would appear to be a relatively stable intrinsic metric. In spite of these achievements, the dimension of irregularity was found to be the most variable relative to the other inter-rater correlations. This variability was further supported by the routine pressing of the definition key – which provided the descriptor – “How even is the scar along its course (i.e., bumpy, rough, etc.)?”. The need for viewing the definition suggests face- and content-validity concerns. At the completion of the testing period, participants were invited to provide feedback and several participants suggested that this dimension title be changed to “Texture”. During the initial dimension gathering and

face-validity exercise, “Texture” was indeed suggested as an alternative title to “Irregularity”, and thus a subsequent study will contrast these two terms to ensure optimal face-validity going forward.

Post-testing feedback also elucidated an additional dimension that had been missed in the original dimension gathering process – the concept of scar impact. Participants suggested that while the scaled dimensions allowed for scar characterization, they neglected to capture the relevance of the scar– i.e., a small scar on the forehead may be considered less relevant/impactful than an identical scar of the mid-cheek. The impact of scar location, its relevance to the surrounding structures, and its relevance to the face as a whole, are central to the concept of scar severity and thus must be included in a valid scar outcome measure. Since the time of the outset of this investigation, Godoy and colleagues (2011) demonstrated that facial lesion size and location to impart a facial “attractiveness penalty” – with larger and more central facial lesions more negatively affecting perceived facial attractiveness (Godoy et al., 2011). This finding is consistent with that identified by our scar observers, and subsequent scar scale development and validity testing must incorporate the concept of scar “impact” – i.e., how much of an influence does the scar have on the rest of the face.

In spite of the aforementioned concerns, the scar dimensions of width, height, pliability, discolouration, distortion, evidence of surgery, and camouflage appear to be reliably and consistently evaluated using the visual-analog scaling paradigm. This testing paradigm improves upon the mathematical assumption limitations of previous scar evaluation scales (Brandt et al., 2009) while also demonstrating superior reliability (see Table 4.5). Thus, the initial validation of the proposed scar dimensions and testing

paradigm provides empirical support for the establishment of a novel scar evaluation scale termed the Scar Camouflage Scale. Planned subsequent investigations will further validate and refine this scale to ensure clinical reliability, while also integrating the findings of this investigation.

**Table 4.5**

*Comparison of Scar Camouflage Scale to other Scar Rating Scales\**

Scale	Year	Intra-rater reliability	Inter-rater reliability
VSS	1990	Acceptable ( $\alpha = 0.71 - 0.79$ )	Poor to Moderate (ICC = 0.03 - 0.64)
MSS	1998	N/A	Good (Spearman's 0.87)
OSAS	2004	Acceptable ( $\alpha = 0.74 - 0.90$ )	Poor to Moderate (ICC = 0.18 - 0.56)
SBSES	2007	N/A	Good (Spearman's 0.73 to 0.85)
SCS	2013	Acceptable to Excellent ( $\alpha = 0.74 - 0.92$ )	Acceptable to Excellent ( $\alpha = 0.78$ to 0.96)

\*Adapted from Vercelli et al., 2003.

Key. VSS = Vancouver Scar Scale; MSS = Manchester Scar Scale; OSAS = Observer Scar Assessment Scale; SBSES = Stony Brook Scar Evaluation Scale; SCS = Scar Camouflage Scale, ICC = Intraclass Correlation Coefficient.

Note. Intra- and inter-rater reliability for contemporary scar evaluation scales. Intra-rater reliability are presented as Crohnbach's alpha. Inter-rater reliability presented as Intraclass Correlation Coefficient, Spearman's coefficient, or Cronbach's alpha.

While the initial focus of this investigation sought to identify scar dimensions that could be scaled and subsequently develop a novel scar scale, a secondary focus was the development and testing of a novel scar-rating program (ScaRS program). Participants reported that the software was intuitive and easy to use. Additionally, observers indicated that the organizational presentation of the scar photograph, along with the series of dimensions to be rated were easily understood and that the ability to manually adjust the slider on each dimensional scale facilitated their ability to rate each dimension in an independent fashion. As such, they reported the ability to quantify the characteristics inherent to any given scar photograph without difficulty. This general finding suggests that the ability to employ the current software within a clinical environment is not only feasible, but of little burden to observers. Furthermore, the substantial time savings of automated quantifying of visual-analog ratings, the unrestricted incorporation and manipulation of scalable dimensions, and the randomization of both the scalable dimensions and photographs presented, provide for an invaluable tool in the evaluation of scars and/or other features of photographs.

## **Conclusions**

Subjective scar dimensions can be reliably measured using a visual-analog scaling paradigm. The results achieved provide preliminary empirical support for the validation of the Scar Camouflage Scale while also suggesting direction for future investigation.

The ScaRS program provides an intuitive means of photographic evaluation and rating that can be employed in subsequent validity testing. These achievements establish a strong foundation for future scar evaluation, with the goal of objectively evaluating scars and the methods of improving them.

## Chapter 5: Conclusions and Bringing it all Together

Thus far this work has highlighted the most common mechanism for acquiring a facial scar (i.e., skin cancer), the biopsychosocial implications of facial scarring, and the elements central to scar evaluation and objective scaling. This chapter will review and integrate these concepts, highlight the clinical implications of this work, and discuss potential directions for future research. Before concluding, a discussion of the limitations of the present work will be addressed.

### Skin Cancer

Skin cancer is a common disease, so frequent that one in every three newly diagnosed cancers is skin cancer (Vogel, 2018). Canadians are particularly susceptible to this disease with Canada being ranked 19 of 62 countries relative to skin cancer susceptibility (Vogel, 2018). Primarily due to direct sun exposure, the head and neck region is the most commonly affected area with up to 80% of skin cancers affecting this vital region (Subramaniam et al., 2017). As was originally outlined, the burden of facial skin cancer is substantial and multifactorial on an individual and societal level. Not only is an individual confronted with the anxiety provoking diagnosis of a cancer, but frequently the malignancy is obvious and intrinsically disfiguring resulting in social isolation. Chapter 2 provides a thorough review of contemporary skin cancer management; the common theme being that surgery is the gold-standard treatment. Surgery is not benign and without its own morbidities. Surgical patients are anxious about the surgery itself, the risks associated with the procedure, post-operative healing concerns, and the prospect of a disfiguring scar (Brandt et al., 2012; Yeung et al., 2014). Given these morbidities a societal shift has focused on skin cancer risk minimization –

i.e., avoiding high UV periods, covering up exposed skin, and using sunscreen. In spite of these minimization strategies, over 3 million cases of non-melanoma skin cancer present annually worldwide (Vogel, 2018). Thus, a concerted effort continues to focus on minimizing treatment related morbidity through well-camouflaged reconstructive surgery and scar minimization.

### **Facial Scarring**

The negative psychological impact of an acquired facial scar has been well documented (Borah & Rankin, 2010; Brown et al., 2008; Ishii et al., 2009; Kim et al., 2013; Levine et al., 2005; Rankin & Borah, 2003; Sobanko et al., 2015; Tebble et al., 2006; Van Den Elzen et al., 2012). Predictably an entire industry has been built around the aesthetic improvement of scars with limited empiric evidence to support commercial promises (Brandt et al., 2009). Similar to commerce and in-part to minimize scarring, many surgical interventions have shifted focus to becoming “minimal access”, “key-hole”, or “incisionless”. Thus, the focus on scar minimization has been paramount in both medical and para-medical cultures. Surprisingly and in spite of this focus, there has been no empirically established gold-standard tool for evaluating scars.

### **Scar Scaling**

As highlighted in Chapter 4, contemporary scar scales suffer from conflicts in the dimensions that are scaled, inconsistencies in how these dimensions are scaled, and are inherently flawed relative to the mathematical assumptions underlying their scaling techniques (Brandt et al., 2009). The proposed Scar Camouflage Scale and the rigor by which its preliminary validity testing was established strives to overcome these challenges. Key dimensions for scar evaluation were identified and refined through this



preliminary validity testing and are summarized in Table 5.1. One of the findings from our preliminary validity testing was that the dimension “Irregularity” was more variably scaled and based on this finding, “Texture” is proposed as an improved hinge word for this dimension. Future investigations will need to compare this to the original “Irregularity” data set. Further, the dimension of “Impact” was proposed as a means of capturing the effect of the scar on the individual’s overall appearance – a unique dimension that to our knowledge, has not previously been captured in the scar evaluation literature.

**Table 5.1:** *Scar Evaluation Dimensions*

<b><u>Dimensions</u></b>
Width
Height
Pliability
Discoloration
Texture
Distortion*
Evidence of Surgery
Camouflage
Impact**

Note. \*Texture replaces “Irregularity” and \*\*Impact is a newly proposed dimension.

Thus, based on the work highlighted in Chapter 4, empiric evidence has been established to support the development of the Scar Camouflage Scale as an effective and reliable means of scar evaluation. Nevertheless, more work must be done to refine this scale to ensure real-world applicability.

### **Clinical Implications**

While some components of empiric scar scaling appeals to academic curiosity, the ability to accurately and objectively evaluate a scar forms the foundation for real clinical work. This is so fundamental, that at present health care providers do not even have an accurate way of documenting or discussing a scar beyond “it’s good” or “it’s bad”. Providing an objective and reliable method for documenting scar severity sets the stage for real-world applicability.

Armed with a reliable scar scale we can begin to understand and appreciate the factors – both positive and negative – that determine individual scar acceptability. This knowledge provides the basis for comprehensive pre-operative counselling. Factors identified as “protective” against negative scar acceptability can potentially be fostered to improve an individual’s capacity for scar acceptance. Alternatively, the identification of “hindering” factors can allow for early counselling and intervention. This step provides the means of moving beyond the scar itself and allowing the integration of the psychosocial factors that contribute to an individual’s overall well-being and social participation.

While wholistic patient care is the goal of any medical intervention, a reliable scar scale also provides the basis for improving scars themselves. A “good” post-operative scar is an outcome believed to result from favorable patient wound-healing biology,

meticulous surgical technique, and conscientious wound aftercare. Curiously, surgical technique and wound aftercare are non-standardized and largely the dogma of apprenticeship surgical training. It is not uncommon to hear surgical trainees ask their expert mentor's why a particular technique is used and be told "this is how we've done it for decades". Anecdotal experience has been the longstanding basis of surgical training. The Scar Camouflage Scale provides an instrument by which surgical wound closure technique and aftercare can be empirically investigated. Does a particular angle of incision, suturing technique, type of suture, or aftercare strategy result in superior scars? Why is it that some surgeons can achieve better scars than others? The answers to these questions have the potential to fundamentally change the way surgical wounds are closed and cared for worldwide.

### **Directions for Future Research**

Standardized scar evaluation is the bottleneck to holistically understanding skin scarring as a health condition. As discussed in Chapter 3, any attempt to apply the ICF framework or more simply to evaluate the psychosocial consequences of a facial scar relies on the ability to accurately characterize a scar. We implicitly understand that a more self-conscious individual will be more psychosocially affected by a scar, but how self-conscious do they need to be, what is the smallest scar that contributes to this outcome, and how does this consequence translate to their social or vocational functioning? The Scar Camouflage Scale provides the necessary basis for addressing these questions as it provides the fundamental objective quantification of the scar itself. The scaled scar measurement can then be hinged to multiple demographic features including age, gender, socioeconomic status, etc., and subsequently compared to

validated quality of life metrics and patient reported outcome measures to provide truly meaningful insight on the scar specific factors that most contribute to positive or negative psychosocial outcomes.

The preliminary testing of the Scar Camouflage Scale included the development of the SCaRS Rating Software. This provided a time-efficient means of acquiring scar rating data. While a research tool used in a lab is fundamental to scar characterization research, prospectively modifying the software to create a scar rating handheld device application (i.e., iOS, Google, etc.) could provide a means of acquiring massive amounts of data from a robust worldwide population. This app could potentially allow for the largest possible scar evaluation study – providing an entirely new way of acquiring scar evaluation data.

As hinted at previously, how an individual views their own scar is vital to their acceptance of the scar and the effects of that scar on their social and vocational functioning (Tebble et al., 2006). The “impact” of the scar on their perceived appearance and the subsequent ramifications are a critical area for future research. Further, identifying the relationship between objective and subjective “impact” is critical to pre-operative patient counselling. To this end, further validity testing is necessary to determine how well the Scar Camouflage Scale captures an individual’s subjective self-rating of their own scar. Once established, self-ratings of scars can then be compared to objective evaluations of the same scar by neutral observers. These results alongside individual demographics and well validated self-consciousness and anxiety outcome measures such as the Derriford Appearance Scale (Harris & Carr, 2001) will yield critical information that will change how we understand facial scarring.

## **Limitations of the Present Project**

The goal of this body of work was to highlight our understanding of facial scarring and provide a means of improving upon current scar evaluation scales. Like all research it is not without its limitations.

To allow for scientific rigor and standardization, the photographs of the scars presented to the participants of the reliability testing of Chapter 4 were exclusively photos of linear (i.e., straight line) scars of varying severity. As we know, scars come in a variety of shapes and sizes which can include wide burn scars, narrow surgical scars, or flat skin graft donor site scars. Thus, the utility of the Scar Camouflage Scale will need to be determined amongst a more broad range of scars.

The participants who served as scar observers and scar raters in our Scar Camouflage Scale reliability testing were derived from a population of volunteer university students, university employees, and hospital workers from Southwestern Ontario. While the age range of participants was quite broad (19 to 63 years), most of these participants were women (25 out of 34). It is expected, that perceived scar severity varies across many factors which may include socioeconomic status, gender, culture, race, religion, and country. Thus, while our reliability testing demonstrated stable results even amongst a small pool of participants, result stability may vary when applied to a larger more diverse population. Further work must thus be done to validate the scar camouflage scale.

Similar to the aforementioned concerns relative to a particular sample size, the utility of the Scar Camouflage Scale has not been determined amongst individuals with scars themselves or professional scar observers. Conceivably acquiring a scar impacts

how one perceives scar severity. Professional observers – i.e., those who regularly care for scars as part of their vocation (i.e., nurse, surgeon, etc.) – may view scars differently than non-professional observers. Perhaps surgically creating scars, visualizing the outcome of this work, or professionally caring for scars may alter one’s internal gauge for determining scar outcomes. To this end, further validity testing is necessary within these population groups and between these population groups as the results define the true applicability of the Scar Camouflage Scale.

Finally, this work is current as of its writing and is likely not the only investigation focusing on scar evaluation. While every effort was made to integrate the latest investigations on scar outcomes, given the velocity of scientific research, it is possible that a novel and very reliable scar scale could be in the process of validity testing that is superior to the current work. While this possibility exists, the numerous directions for future research remain important goals that can be achieved irrespective of the specific measurement tool applied – albeit the tool must be rigorously validated.

## **Summary**

In summary, facial skin scarring is a substantial problem with a real and tangible impact on an individual’s self-perceived attractiveness, self-esteem, social acceptance, and overall societal and vocational functioning. This body of research has reviewed the challenges associated with facial skin scars, the most common mechanism by which facial scars are obtained (i.e., skin cancer) and the need for more holistic approaches to scar characterization and measurement.

The robust development of a novel scar evaluation scale was proposed. It is encouraging that our preliminary validity testing provides a springboard for future

research. Findings of this research have the potential to help understand the factors that impact skin scar development and thereby direct caregivers in their efforts towards scar minimization. At the same time, future research can be directed to the factors that impact upon subjective and objective scar characterization and acceptability, ideally with the goal of improving direct patient counselling both pre- and post-scar development.

In seeking to establish a novel scar evaluation scale, the unique SCaRS Rating Software was developed. This tool provides a robust, adaptable, and time-efficient means for acquiring enormous amounts of scar rating data (i.e., nine-dimension measurements for each scar photo for every scar observer). Thus, we now have the scar rating tool, the timesaving software, and a means of data acquisition to propel clinical scar research forward.

In conclusion, this work has provided the background and direction for a robust program of research into the evolution and impact of scars. Consequently, the outcome of this research has the potential to impact on every individual who acquires a scar through any means. While scars may be inevitable, we now have the background and tools available to minimize the scars of the future and the impact on those we serve.

## References

- Albert, M. R., & Weinstock, M. A. (2003). Keratinocyte Carcinoma. *CA: A Cancer Journal for Clinicians*, 53(5), 292–302. <https://doi.org/10.3322/canjclin.53.5.292>
- Ang, G. C., Roenigk, R. K., Otley, C. C., Kim Phillips, P., & Weaver, A. L. (2009). More than 2 decades of treating atypical fibroxanthoma at mayo clinic: What have we learned from 91 patients? *Dermatologic Surgery*, 35(5), 765–772. <https://doi.org/10.1111/j.1524-4725.2009.01126.x>
- Baryza, M. J., & Baryza, G. A. (1995). The vancouver scar scale: An administration tool and its interrater reliability. *Journal of Burn Care and Rehabilitation*, 16(5), 535–538. <https://doi.org/10.1097/00004630-199509000-00013>
- Beausang, E., Floyd, H., Dunn, K. W., Orton, C. I., & Ferguson, M. W. J. (1998). A new quantitative scale for clinical scar assessment. *Plastic and Reconstructive Surgery*, 102(6), 1954–1961. <https://doi.org/10.1097/00006534-199811000-00022>
- Blake, P. W., Bradford, P. T., Devesa, S. S., & Toro, J. R. (2010). Cutaneous appendageal carcinoma incidence and survival patterns in the United States: A population-based study. *Archives of Dermatology*, 146(6), 625–632. <https://doi.org/10.1001/archdermatol.2010.105>
- Bock, O., Schmid-Ott, G., Malewski, P., & Mrowietz, U. (2006). Quality of life of patients with keloid and hypertrophic scarring. *Archives of Dermatological Research*, 297(10), 433–438. <https://doi.org/10.1007/s00403-006-0651-7>
- Borah, G. L., & Rankin, M. K. (2010). Appearance is a function of the face. *Plastic and Reconstructive Surgery*, 125(3), 873–878.



<https://doi.org/10.1097/PRS.0b013e3181cb613d>

Bowles, T., Ross, M., & Lazar, A. (2011). *Cancer of the Skin* (pp. 157–167). Elsevier.

Brandt, M. G., Franklin, J. H., Osborn, H. A., Fung, K., Yoo, J., & Doyle, P. C. (2012).

The western surgical concern inventory-thyroid: Development and initial validation.

*Otolaryngology - Head and Neck Surgery (United States)*, 147(2), 227–232.

<https://doi.org/10.1177/0194599812443041>

Brandt, M. G., Moore, C. C. (2019). Nonmelanoma Skin Cancer. *Facial plastic surgery*

*clinics of North America*, 27(1), 1-13. [https://doi: 10.1016/j.fsc.2018.08.001](https://doi:10.1016/j.fsc.2018.08.001)

Brandt, M. G., Moore, C. C., Micomonaco, D., Fung, K., Franklin, J. H., Yoo, J., &

Doyle, P. C. (2009). A Prospective randomized evaluation of scar assessment

measures. *Laryngoscope*, 119(5), 841–845. <https://doi.org/10.1002/lary.20139>

Brodland, D. G., & Zitelli, J. A. (1992). Surgical margins for excision of primary

cutaneous squamous cell carcinoma. *Journal of the American Academy of*

*Dermatology*, 27(2), 241–248. [https://doi.org/10.1016/0190-9622\(92\)70178-I](https://doi.org/10.1016/0190-9622(92)70178-I)

Brown, B. C., McKenna, S. P., Siddhi, K., McGrouther, D. A., & Bayat, A. (2008). The

hidden cost of skin scars: quality of life after skin scarring. *Journal of Plastic,*

*Reconstructive and Aesthetic Surgery*, 61(9), 1049–1058.

<https://doi.org/10.1016/j.bjps.2008.03.020>

Brown, B. C., Moss, T. P., McGrouther, D. A., & Bayat, A. (2010). Skin scar

preconceptions must be challenged: Importance of self-perception in skin scarring.

*Journal of Plastic, Reconstructive and Aesthetic Surgery*, 63(6), 1022–1029.

<https://doi.org/10.1016/j.bjps.2009.03.019>

Canadian Cancer Society. (2014). Canadian Cancer Statistics Special topic : Skin cancers.

<https://www.cancer.ca/en/cancer-information/cancer-101/canadian-cancer-statistics/past-editions-canadian-cancer-statistics/?region=en>

Cassileth, B. R., Lusk, E. J., & Tenaglia, A. N. (1983). Patients' perceptions of the cosmetic impact of melanoma resection. *Plastic and Reconstructive Surgery*, 71(1), 73–75. <https://doi.org/10.1097/00006534-198301000-00016>

Chen, L., Silapunt, S., & Migden, M. R. (2016). Sonidegib for the treatment of advanced basal cell carcinoma: A comprehensive review of sonidegib and the BOLT trial with 12-month update. In *Future Oncology* (Vol. 12, Issue 18, pp. 2095–2105). <https://doi.org/10.2217/fon-2016-0118>

Criscione, V. D., & Weinstock, M. A. (2007). Descriptive epidemiology of dermatofibrosarcoma protuberans in the United States, 1973 to 2002. *Journal of the American Academy of Dermatology*, 56(6), 968–973. <https://doi.org/10.1016/j.jaad.2006.09.006>

Dei Tos, A. P., Maestro, R., Doglioni, C., Gasparotto, D., Boiocchi, M., Laurino, L., & Fletcher, C. D. M. (1994). Ultraviolet-induced p53 mutations in atypical fibroxanthoma. *American Journal of Pathology*, 145(1), 11–17.

Dey, J. K., Ishii, L. E., Byrne, P. J., Boahene, K. D. O., & Ishii, M. (2015). The social penalty of facial lesions: New evidence supporting high-quality reconstruction. *JAMA Facial Plastic Surgery*, 17(2), 90–96. <https://doi.org/10.1001/jamafacial.2014.1131>

Dey, J. K., Ishii, M., Boahene, K. D. O., Byrne, P., & Ishii, L. E. (2015). Impact of facial

defect reconstruction on attractiveness and negative facial perception.

*Laryngoscope*, 125(6), 1316–1321. <https://doi.org/10.1002/lary.25130>

Draaijers, L. J., Tempelman, F. R. H., Botman, Y. A. M., Tuinebreijer, W. E.,

Middelkoop, E., Kreis, R. W., & Van Zuijlen, P. P. M. (2004). The Patient and Observer Scar Assessment Scale: A reliable and feasible tool for scar evaluation.

*Plastic and Reconstructive Surgery*, 113(7), 1960–1965.

<https://doi.org/10.1097/01.PRS.0000122207.28773.56>

Duncan, J. A. L., Bond, J. S., Mason, T., Ludlow, A., Cridland, P., O’Kane, S., &

Ferguson, M. W. J. (2006). Visual analogue scale scoring and ranking: A suitable and sensitive method for assessing scar quality? *Plastic and Reconstructive Surgery*,

118(4), 909–918. <https://doi.org/10.1097/01.prs.0000232378.88776.b0>

Durani, P., McGrouther, D. A., & Ferguson, M. W. J. (2009). Current scales for assessing

human scarring: A review. In *Journal of Plastic, Reconstructive and Aesthetic*

*Surgery* (Vol. 62, Issue 6, pp. 713–720). <https://doi.org/10.1016/j.bjps.2009.01.080>

Eadie, T. L., & Doyle, P. C. (2002a). Direct magnitude estimation and interval scaling of

naturalness and severity in tracheoesophageal (TE) speakers. *Journal of Speech,*

*Language, and Hearing Research*, 45(6), 1088–1096. [https://doi.org/10.1044/1092-](https://doi.org/10.1044/1092-4388(2002/087))

[4388\(2002/087\)](https://doi.org/10.1044/1092-4388(2002/087))

Eadie, T. L., & Doyle, P. C. (2002b). Direct magnitude estimation and interval scaling of

pleasantness and severity in dysphonic and normal speakers. *The Journal of the*

*Acoustical Society of America*, 112(6), 3014–3021.

<https://doi.org/10.1121/1.1518983>

- Eadie, T. L., & Doyle, P. C. (2005). Scaling of voice pleasantness and acceptability in tracheoesophageal speakers. *Journal of Voice*, *19*(3), 373–383.  
<https://doi.org/10.1016/j.jvoice.2004.04.004>
- Engel, G. L. (1977). The need for a new medical model: A challenge for biomedicine. *Science*, *196*(4286), 129–136. <https://doi.org/10.1126/science.847460>
- Feng, H., Shuda, M., Chang, Y., & Moore, P. S. (2008). Clonal integration of a polyomavirus in human Merkel cell carcinoma. *Science*, *319*(5866), 1096–1100.  
<https://doi.org/10.1126/science.1152586>
- Gailani, M. R., Leffell, D. J., Ziegler, A. M., Gross, E. G., Brash, D. E., & Bale, A. E. (1996). Relationship between sunlight exposure and a key genetic alteration in basal cell carcinoma. *Journal of the National Cancer Institute*, *88*(6), 349–354.  
<https://doi.org/10.1093/jnci/88.6.349>
- Godoy, A., Ishii, M., Byrne, P. J., Boahene, K. D. O., Encarnacion, C. O., & Ishii, L. E. (2011). How facial lesions impact attractiveness and perception: Differential effects of size and location. *Laryngoscope*, *121*(12), 2542–2547.  
<https://doi.org/10.1002/lary.22334>
- Harms, K. L., Healy, M. A., Nghiem, P., Sober, A. J., Johnson, T. M., Bichakjian, C. K., & Wong, S. L. (2016). Analysis of Prognostic Factors from 9387 Merkel Cell Carcinoma Cases Forms the Basis for the New 8th Edition AJCC Staging System. *Annals of Surgical Oncology*, *23*(11), 3564–3571. <https://doi.org/10.1245/s10434-016-5266-4>
- Harris, D. L., & Carr, A. T. (2001). The Derriford Appearance Scale (DAS59): A new

psychometric scale for the evaluation of patients with disfigurements and aesthetic problems of appearance. *British Journal of Plastic Surgery*, 54(3), 216–222.

<https://doi.org/10.1054/bjps.2001.3559>

Heath, M., Jaimes, N., Lemos, B., Mostaghimi, A., Wang, L. C., Peñas, P. F., & Nghiem, P. (2008). Clinical characteristics of Merkel cell carcinoma at diagnosis in 195 patients: the AEIOU features. *Journal of the American Academy of Dermatology*, 58(3), 375–381. <https://doi.org/10.1016/j.jaad.2007.11.020>

Holden, C. A., Spittle, M. F., & Jones, E. W. (1987). Angiosarcoma of the face and scalp, prognosis and treatment. *Cancer*, 59(5), 1046–1057. [https://doi.org/10.1002/1097-0142\(19870301\)59:5<1046::AID-CNCR2820590533>3.0.CO;2-6](https://doi.org/10.1002/1097-0142(19870301)59:5<1046::AID-CNCR2820590533>3.0.CO;2-6)

Idriss, N., & Maibach, H. I. (2009). Scar assessment scales: A dermatologic overview. In *Skin Research and Technology* (Vol. 15, Issue 1, pp. 1–5). <https://doi.org/10.1111/j.1600-0846.2008.00327.x>

Ishii, L., Carey, J., Byrne, P., Zee, D. S., & Ishii, M. (2009). Measuring attentional bias to peripheral facial deformities. *Laryngoscope*, 119(3), 459–465. <https://doi.org/10.1002/lary.20132>

Kantor, J. (2016). The SCAR (Scar Cosmesis Assessment and Rating) scale: development and validation of a new outcome measure for postoperative scar assessment. In *British Journal of Dermatology* (Vol. 175, Issue 6, pp. 1394–1396). <https://doi.org/10.1111/bjd.14812>

Kapp-Simon, K. (1986). Self-concept of primary-school-age children with cleft lip, cleft palate, or both. *Cleft Palate Journal*, 23(1), 24–27.

Kim, Y. J., Park, J. W., Kim, J. M., Park, S. H., Hwang, J. H., Kim, K. S., Lee, S. Y., & Shin, J. H. (2013). The functionality of facial appearance and its importance to a Korean population. *Archives of Plastic Surgery*, *40*(6), 715–720.

<https://doi.org/10.5999/aps.2013.40.6.715>

Klassen, A. F., Ziolkowski, N., Mundy, L. R., Miller, H. C., McIlvride, A., Dilaura, A., Fish, J., & Pusic, A. L. (2018). Development of a new patient-reported outcome instrument to evaluate treatments for scars: The SCAR-Q. *Plastic and Reconstructive Surgery - Global Open*, *6*(4).

<https://doi.org/10.1097/GOX.0000000000001672>

Lee, C. J. (2004). Horatio (Version 3.0) [Computer Software]. London, Ontario, Canada.

<http://publish.uwo.ca/~cjlee/horatio/index.html>

Lee, D. A., & Miller, S. J. (2009). Nonmelanoma Skin Cancer. In *Facial Plastic Surgery Clinics of North America* (Vol. 17, Issue 3, pp. 309–324).

<https://doi.org/10.1016/j.fsc.2009.04.004>

Levine, E., Degutis, L., Pruzinsky, T., Shin, J., & Persing, J. A. (2005). Quality of life and facial trauma: Psychological and body image effects. *Annals of Plastic Surgery*,

*54*(5), 502–510. <https://doi.org/10.1097/01.sap.0000155282.48465.94>

Love, B., Byrne, C., Roberts, J., Browne, G., & Brown, B. (1987). Adult psychosocial adjustment following childhood injury: The effect of disfigurement. *Journal of Burn Care and Rehabilitation*,

*8*(4), 280–284. [https://doi.org/10.1097/00004630-](https://doi.org/10.1097/00004630-198707000-00008)

[198707000-00008](https://doi.org/10.1097/00004630-198707000-00008)

Madan, V., Lear, J. T., & Szeimies, R. M. (2010). Non-melanoma skin cancer. In *The*

*Lancet* (Vol. 375, Issue 9715, pp. 673–685). [https://doi.org/10.1016/S0140-6736\(09\)61196-X](https://doi.org/10.1016/S0140-6736(09)61196-X)

Malt, U. F., & Ugland, O. M. (1989). A long-term psychosocial follow-up study of burned adults. *Acta Psychiatrica Scandinavica*, 80, 94–102.  
<https://doi.org/10.1111/j.1600-0447.1989.tb05259.x>

Matsui, M. S., & DeLeo, V. A. (1991). Longwave ultraviolet radiation and promotion of skin cancer. In *Cancer Cells* (Vol. 3, Issue 1, pp. 8–12).

McArthur, G. (2004). Molecularly targeted treatment for dermatofibrosarcoma protuberans. *Seminars in Oncology*, 31(SUPPL. 6), 30–36.  
<https://doi.org/10.1053/j.seminoncol.2004.03.038>

Mendenhall, W. M., Mendenhall, C. M., Werning, J. W., Reith, J. D., & Mendenhall, N. P. (2006). Cutaneous angiosarcoma. In *American Journal of Clinical Oncology: Cancer Clinical Trials* (Vol. 29, Issue 5, pp. 524–528).  
<https://doi.org/10.1097/01.coc.0000227544.01779.52>

Mokhtar, G. A. (2009). Squamous cell carcinoma of the breast. In *Saudi Medical Journal* (Vol. 30, Issue 10, pp. 1346–1349).

National Comprehensive Cancer Network (NCCN). (2019a). *NCCN Clinical Practice Guidelines in Oncology. Basal Cell Skin Cancer (Version 1.2020)*.  
[https://www.nccn.org/professionals/physician\\_gls/pdf/nmsc.pdf](https://www.nccn.org/professionals/physician_gls/pdf/nmsc.pdf)

National Comprehensive Cancer Network (NCCN). (2019d). *NCCN Clinical Practice Guidelines in Oncology. Dermatofibrosarcoma Protuberans (Version 1.2020)*.  
[https://www.nccn.org/professionals/physician\\_gls/pdf/dfsp.pdf](https://www.nccn.org/professionals/physician_gls/pdf/dfsp.pdf)

National Comprehensive Cancer Network (NCCN). (2019c). *NCCN Clinical Practice Guidelines in Oncology. Merkel Cell Carcinoma (Version 1.2020)*.

[https://www.nccn.org/professionals/physician\\_gls/pdf/mcc.pdf](https://www.nccn.org/professionals/physician_gls/pdf/mcc.pdf)

National Comprehensive Cancer Network (NCCN). (2019b). *NCCN Clinical Practice Guidelines in Oncology. Squamous Cell Skin Cancer (Version 1.2020)*.

[https://www.nccn.org/professionals/physician\\_gls/pdf/squamous.pdf](https://www.nccn.org/professionals/physician_gls/pdf/squamous.pdf)

Nghiem, D. X., Kazimi, N., Mitchell, D. L., Vink, A. A., Ananthaswamy, H. N., Kripke, M. L., & Ullrich, S. E. (2002). Mechanisms underlying the suppression of established immune responses by ultraviolet radiation. *Journal of Investigative Dermatology*, *119*(3), 600–608. <https://doi.org/10.1046/j.1523-1747.2002.01845.x>

Norval, M., Kellett, P., & Wright, C. Y. (2014). The incidence and body site of skin cancers in the population groups of south africa. *Photodermatology Photoimmunology and Photomedicine*, *30*(5), 262–265.

<https://doi.org/10.1111/phpp.12106>

Okkerse, J. M. E., Beemer, F. A., Cordia-de Haan, M., Heineman-de Boer, J. A., Mellenbergh, G. J., & Wolters, W. H. G. (2001). Facial attractiveness and facial impairment ratings in children with craniofacial malformations. *Cleft Palate-Craniofacial Journal*, *38*(4), 386–392. [https://doi.org/10.1597/1545-1569\(2001\)038<0386:FAAFIR>2.0.CO;2](https://doi.org/10.1597/1545-1569(2001)038<0386:FAAFIR>2.0.CO;2)

Orchard, G. E., Zelger, B., Wilson Jones, E., & Russell Jones, R. (1996). An immunocytochemical assessment of 19 cases of cutaneous angiosarcoma. *Histopathology*, *28*(3), 235–240. <https://doi.org/10.1046/j.1365-2559.1996.d01-411.x>

411.x



- Perry, D. M., McGrouther, D. A., & Bayat, A. (2010). Current tools for noninvasive objective assessment of skin scars. *Plastic and Reconstructive Surgery*, *126*(3), 912–923. <https://doi.org/10.1097/PRS.0b013e3181e6046b>
- Pillemer, F. G., & Cook, K. V. (1989). The psychosocial adjustment of pediatric craniofacial patients after surgery. *Cleft Palate Journal*, *26*(3), 201–207.
- Pope, A. W., & Ward, J. (1997). Self-perceived facial appearance and psychosocial adjustment in preadolescents with craniofacial anomalies. *Cleft Palate-Craniofacial Journal*, *34*(5), 396–401. [https://doi.org/10.1597/1545-1569\(1997\)034<0396:SPFAAP>2.3.CO;2](https://doi.org/10.1597/1545-1569(1997)034<0396:SPFAAP>2.3.CO;2)
- Ramstad, T., Ottem, E., & Shaw, W. C. (1995). Psychosocial adjustment in Norwegian adults who had undergone standardised treatment of complete cleft lip and palate II. Self-reported problems and concerns with appearance. *Scandinavian Journal of Plastic and Reconstructive Surgery and Hand Surgery*, *29*(4), 329–336. <https://doi.org/10.3109/02844319509008968>
- Rankin, M., & Borah, G. L. (2003). Perceived functional impact of abnormal facial appearance. *Plastic and Reconstructive Surgery*, *111*(7), 2140–2146. <https://doi.org/10.1097/01.PRS.0000060105.63335.0C>
- Reinstadler, D. R., & Sinha, U. K. (2012). Uncommon Cutaneous Neoplasms of the Head and Neck. In *Facial Plastic Surgery Clinics of North America* (Vol. 20, Issue 4, pp. 483–491). <https://doi.org/10.1016/j.fsc.2012.08.002>
- Rogers, H. W., Weinstock, M. A., Feldman, S. R., & Coldiron, B. M. (2015). Incidence estimate of nonmelanoma skin cancer (keratinocyte carcinomas) in the us

population, 2012. *JAMA Dermatology*, 151(10), 1081–1086.

<https://doi.org/10.1001/jamadermatol.2015.1187>

Roques, C., & Téot, L. (2007). Reviews: A critical analysis of measurements used to assess and manage scars. In *International Journal of Lower Extremity Wounds* (Vol. 6, Issue 4, pp. 249–253). <https://doi.org/10.1177/1534734607308249>

Rouhani, P., Fletcher, C. D. M., Devesa, S. S., & Toro, J. R. (2008). Cutaneous soft tissue sarcoma incidence patterns in the U.S.: An analysis of 12,114 cases. *Cancer*, 113(3), 616–627. <https://doi.org/10.1002/cncr.23571>

Rubin, A. I., Chen, E. H., & Ratner, D. (2005). Basal-cell carcinoma. In *New England Journal of Medicine* (Vol. 353, Issue 21, pp. 2262–2269). <https://doi.org/10.1056/NEJMra044151>

Rumsey, N., Clarke, A., White, P., Wyn-Williams, M., & Garlick, W. (2004). Altered body image: Appearance-related concerns of people with visible disfigurement. *Journal of Advanced Nursing*, 48(5), 443–453. <https://doi.org/10.1111/j.1365-2648.2004.03227.x>

Sangeuza, O., & Requena, L. (2011). *Cancer of the Skin* (2nd Editio, pp. 186–195). Elsevier.

Santamaria-Barria, J. A., Boland, G. M., Yeap, B. Y., Nardi, V., Dias-Santagata, D., & Cusack, J. C. (2013). Merkel cell carcinoma: 30-year experience from a single institution. *Annals of Surgical Oncology*, 20(4), 1365–1373. <https://doi.org/10.1245/s10434-012-2779-3>

Sekulic, A., Migden, M. R., Oro, A. E., Dirix, L., Lewis, K. D., Hainsworth, J. D.,

Solomon, J. A., Yoo, S., Arron, S. T., Friedlander, P. A., Marmur, E., Rudin, C. M., Chang, A. L. S., Low, J. A., Mackey, H. M., Yauch, R. L., Graham, R. A., Reddy, J. C., & Hauschild, A. (2012). Efficacy and safety of vismodegib in advanced basal-cell carcinoma. *New England Journal of Medicine*, *366*(23), 2171–2179.

<https://doi.org/10.1056/NEJMoa1113713>

Singer, A. J., Arora, B., Dagum, A., Valentine, S., & Hollander, J. E. (2007).

Development and validation of a novel scar evaluation scale. *Plastic and Reconstructive Surgery*, *120*(7), 1892–1897.

<https://doi.org/10.1097/01.prs.0000287275.15511.10>

Sobanko, J. F., Sarwer, D. B., Zvargulis, Z., & Miller, C. J. (2015). Importance of

physical appearance in patients with skin cancer. *Dermatologic Surgery*, *41*(2), 183–

188. <https://doi.org/10.1097/DSS.0000000000000253>

Stephens, D. (2001). *World Health Organization's international classification of*

*functioning, disability and health - ICF*. <https://doi.org/WHO/EIP/GPE/CAS/01.3>

Stojadinovic, A., Karpoff, H. M., Antonescu, C. R., Shah, J. P., Singh, B., Spiro, R. H.,

Dumornay, W., & Shaha, A. R. (2000). Dermatofibrosarcoma protuberans of the head and neck. *Annals of Surgical Oncology*, *7*(9), 696–704.

<https://doi.org/10.1007/s10434-000-0696-3>

Subramaniam, P., Olsen, C. M., Thompson, B. S., Whiteman, D. C., & Neale, R. E.

(2017). Anatomical distributions of basal cell carcinoma and squamous cell carcinoma in a population-based study in Queensland, Australia. *JAMA*

*Dermatology*, *153*(2), 175–182. <https://doi.org/10.1001/jamadermatol.2016.4070>

- Sullivan, T., Smith, J., Kermode, J., McIver, E., & Courtemanche, D. J. (1990). Rating the burn scar. *Journal of Burn Care and Rehabilitation*, 11(3), 256–260.  
<https://doi.org/10.1097/00004630-199005000-00014>
- Tebble, N. J., Adams, R., Thomas, D. W., & Price, P. (2006). Anxiety and self-consciousness in patients with facial lacerations one week and six months later. *British Journal of Oral and Maxillofacial Surgery*, 44(6), 520–525.  
<https://doi.org/10.1016/j.bjoms.2005.10.010>
- Tessier, P. (1976). Anatomical classification of facial, cranio-facial and latero-facial clefts. *Journal of Maxillofacial Surgery*, 4(C), 69–92. [https://doi.org/10.1016/S0301-0503\(76\)80013-6](https://doi.org/10.1016/S0301-0503(76)80013-6)
- Tetzlaff, M. T., & Nagarajan, P. (2018). Update on Merkel Cell Carcinoma. *Head and Neck Pathology*, 12(1), 31–43. <https://doi.org/10.1007/s12105-018-0898-2>
- Van Den Elzen, M. E. P., Versnel, S. L., Hovius, S. E. R., Passchier, J., Duivenvoorden, H. J., & Mathijssen, I. M. J. (2012). Adults with congenital or acquired facial disfigurement: Impact of appearance on social functioning. *Journal of Cranio-Maxillofacial Surgery*, 40(8), 777–782. <https://doi.org/10.1016/j.jcms.2012.02.010>
- Vercelli, S., Ferriero, G., Sartorio, F., Stissi, V., & Franchignoni, F. (2003). How to assess postsurgical scars: A review of outcome measures. *Disability and Rehabilitation*, 25(31), 2055–2063. <https://doi.org/10.3109/09638280902874196>
- Vogel, L. (2018). Canada among top 20 countries for skin cancer risk. In *CMAJ : Canadian Medical Association journal = journal de l'Association medicale canadienne* (Vol. 190, Issue 32, p. E971). <https://doi.org/10.1503/cmaj.109-5643>

- Walsh, S., & Santa Cruz, D. (2011). *Cancer of the Skin* (pp. 140–149). Elsevier.
- Willis, A. I., & Ridge, J. A. (2007). Discordant lymphatic drainage patterns revealed by serial lymphoscintigraphy in cutaneous head and neck malignancies. *Head and Neck*, 29(11), 979–985. <https://doi.org/10.1002/hed.20631>
- Wolf, D. J., & Zitelli, J. A. (1987). Surgical Margins for Basal Cell Carcinoma. *Archives of Dermatology*, 123(3), 340–344. <https://doi.org/10.1001/archderm.1987.01660270078019>
- Yeung, J. C., Brandt, M. G., Franklin, J. H., Doyle, P. C., Rotenberg, B. W., & Kilty, S. J. (2014). Preoperative concerns of patients undergoing endoscopic sinus surgery. *International Forum of Allergy and Rhinology*, 4(8), 658–662. <https://doi.org/10.1002/alr.21330>

**Appendix A: Health Science Research Ethics Board Approval**

**LAWSON HEALTH RESEARCH INSTITUTE  
CLINICAL RESEARCH IMPACT COMMITTEE**

RESEARCH OFFICE REVIEW NO.: R-06-331

PROJECT TITLE: Psychophysical evaluation of scar assessment scales

PRINCIPAL INVESTIGATOR: Dr. PC Doyle

DATE OF REVIEW BY CRIC: October 18, 2006

HEALTH SCIENCES REB #: 12501E

Please be advised that the above project was reviewed by the Clinical Research Impact Committee and the project:

**Was Approved**

**PLEASE INFORM THE APPROPRIATE NURSING UNITS, LABORATORIES, ETC. BEFORE STARTING THIS PROTOCOL. THE RESEARCH OFFICE NUMBER MUST BE USED WHEN COMMUNICATING WITH THESE AREAS.**

Dr. Joseph J. Gilbert  
Chairman  
Clinical Research Impact Committee

All future correspondence concerning this study should include the Research Office Review Number and should be directed to Sherry Paiva, Room C210, Nurses Residence, South Street Campus.

cc: Administration

## Curriculum Vitae

**Name:** Michael G. Brandt

### Post-secondary education:

- 2012 – Present Faculty of Health Sciences  
Graduate Program in Health & Rehabilitation Sciences  
Rehabilitation Sciences Field  
Western University  
London, Ontario, Canada  
M. Sc. Candidate  
Supervisor: Dr. Philip C. Doyle
- 2010 – 2011 Section of Facial Plastic and Reconstructive Surgery  
Department of Otolaryngology – Head and Neck Surgery  
University of Michigan  
Ann Arbor, Michigan, United States of America  
American Academy of Facial Plastic and Reconstructive Surgery  
Fellowship  
Supervisors: Dr. Shan R. Baker, Dr. Jeffrey S. Moyer
- 2005 – 2010 Department of Otolaryngology – Head and Neck Surgery  
Schulich School of Medicine & Dentistry  
University of Western Ontario  
London, Ontario, Canada  
Residency in Otolaryngology – Head and Neck Surgery
- 2001 – 2005 Schulich School of Medicine & Dentistry  
University of Western Ontario  
London, Ontario, Canada  
M.D.
- 1997 - 2001 York University  
Toronto, Ontario, Canada  
B.Sc. Specialized Honours  
Psychology & Research Methodology

### Peer-reviewed publications:

Osborn HA, Glicksman JT, **Brandt MG**, Doyle PC, Fung K. Primary care specialty career choice among Canadian medical students: Understanding the factors that influence their decisions. Canadian Family Physician. 2017 Feb;63(2):e107-e113.

Rajakumar C, Doyle PC, **Brandt MG**, Moore CC, Nichols A, Franklin JH, Yoo J, Fung K. A paired comparison analysis of third-party rater thyroidectomy scar preference.. Journal of Laryngology & Otology. 2017 Jan;131(1):13-18.

Oyewumi M, **Brandt MG**, Carrillo B, Atkinson A, Iglar K, Forte V, Campisi P. Objective evaluation of otoscopy skills among family and community medicine, pediatric, and Otolaryngology Residents. Journal of Surgical Education. 2016 Jan-Feb; 73(1): 129-35.

Tan SL, **Brandt MG**, Yeung JC, Doyle PC, Moore CC. The aesthetic unit theory of aging. JAMA Facial Plastic Surgery. 2015 Jan 1;17(1):33-38.

Chow W, **Brandt MG**, Dworshak-Stokan A, Doyle PC, Matic D, Husein M. Validation of the mirror-fogging test as a screening tool for velopharyngeal insufficiency. The Open Otorhinolaryngology Journal, 2015, 8: 15-21.

**Brandt MG**, Scott GM, Doyle PC, Ballagh RH. Otolaryngology – Head and Neck Surgeon Unemployment in Canada: a cross-sectional survey of graduating Otolaryngology – Head and Neck Surgery residents. Journal of Otolaryngology – Head and Neck Surgery. 2014 Sept; 43:37.

Yeung JC, **Brandt MG**, Franklin JH, Doyle PC, Rotenberg BW, Kilty SJ. Pre-operative concerns of patients undergoing endoscopic sinus surgery: A multi-institutional, prospective study. International Forum of Allergy & Rhinology. 2014 Aug;4(8):658-62.

**Brandt MG**, Rotenberg BW, Moore CC, Doyle PC. Impact of nasal surgery on speech resonance. Annals of Otology, Rhinology, and Laryngology. 2014 Mar 19;123(8):564-570.

Xu, JJ, Campbell G, Alsaffar H, **Brandt MG**, Doyle PC, Glicksman JT, Fung K. Lymphadenopathy: defining a palpable lymph node. Head & Neck. 2013 Dec 17. [*Epub ahead of print*].

Brichacek MA, **Brandt MG**, Carey JP, Byrne PJ. Stapedial synkinesis causing change in hearing threshold with facial motion. Otology & Neurotology. 2013 Jun;34(4):762-5.

**Brandt MG**, Hassa A, Roth KE, Wehrli B, Moore CC. The hyoplatysmal ligament: characterization and biomechanical properties. Archives of Facial Plastic Surgery. 2012. Sep-Oct;14(5):369-71.

**Brandt MG**, Franklin JH, Osborn HA, Fung K, Yoo J, Doyle PC. The Western Surgical Concern Inventory-Thyroid: development and initial validation. Otolaryngology – Head and Neck Surgery. 2012 Aug; 147(2):227-32.

**Brandt MG**, Hassa A, Roth KE, Wehrli B, Moore CC. Biomechanical properties of the facial retaining ligaments. Archives of Facial Plastic Surgery. 2012 Jul-Aug; 14(4):289-94.



Roach VA, **Brandt MG**, Moore CC, Wilson TD. Is three-dimensional videography the cutting edge of surgical skill acquisition? *Anatomical Sciences Education* 2012 May-Jun; 5(3):138-45.

Abuzeid WM, **Brandt MG**, Moyer JS, Baker SR. MRSA-associated infections following septorhinoplasty: epidemiology, risk stratification, and management guidelines. *Facial Plast Surg*. 2012 Jun;28(3):354-7.

Xu J, Fung K, Glicksman JT, **Brandt MG**, Campbell G. Development of a tissue-mimicking neck model for medical education. *Journal of Otolaryngology – Head and Neck Surgery*. 2012 Apr;41(2):145-51.

Jeremic G, Moore CC, **Brandt MG**, Doyle PC. Neoadjuvant use of photodynamic therapy in basal and squamous cell carcinomas of the face. *ISRN Dermatology*. 2011; 809409. Epub 2011 May 31.

**Brandt MG**, Rotenberg BW, Yeung JC, Franklin JH, Doyle PC. Preoperative concerns in patients considering sinus surgery: initial validation of the Western Surgical Concern Inventory. *American Journal of Rhinology & Allergy*. 2011; 1(3): 219-24.

Abdul-Sater L, Henry M, Majdan A, Mijovic T, Franklin JH, **Brandt MG**, Black MJ, Hier MP, Payne RJ. What are thyroidectomy patients really concerned about? *Otolaryngology – Head and Neck Surgery*. 2011; 144(5):685-90.

Jeremic G, **Brandt MG**, Jordan K, Doyle PC, Yu E, Moore CC. Using photodynamic therapy as a neoadjuvant treatment in the surgical excision of non-melanotic skin cancers: a prospective study. *Journal of Otolaryngology - Head and Neck Surgery*. 2011; 40(1):S82-9.

**Brandt MG**, Franklin JH, Moore CC. Direct nasolabial lift for the palliation of oncologic lower-face paralysis. *Journal of Otolaryngology - Head and Neck Surgery*. 2010; 39(4):476-8.

**Brandt MG**, Husein M, Matic D, Leung A, Wehrli B, Welch I, Doyle PC. Atrophy amongst mucosa only versus muscular mucosa superiorly based pharyngeal flaps. *Plastic & Reconstructive Surgery*. 2010; 125(6):1679-84.

**Brandt MG**, Poirier J, Hughes B, Lownie SP, Parnes LS. The transcrural approach: a 10-year experience at one Canadian center. *Neurosurgery*. 2010; 66(5):1017-22.

**Brandt MG**, Al Gilani M, Balderston J, Davidson R, Moore CC, Taylor SM. Microbiologic assessment of multidose Restylane® for facial augmentation. *Archives of Facial Plastic Surgery*. 2009; 11(4):271-3.

**Brandt MG**, Moore CC, Micomonaco D, Fung K, Franklin JH, Yoo J, Doyle PC. A prospective randomized evaluation of scar assessment measures. *Laryngoscope*. 2009; 119(5):841-5.

Glicksman JT, **Brandt MG**, Moukarbel RV, Rotenberg B, Fung K. The use of computer-assisted learning to acquire psychomotor skills in epistaxis management. *Laryngoscope*. 2009; 119(3):466-72.

Micomonaco D, Fung K, Franklin JH, Yoo J, **Brandt M**, Moore CC. Development of a new visual analog scale for the assessment of area scars. *Journal of Otolaryngology - Head and Neck Surgery*. 2009; 38(1):77-89.

Glicksman JT, **Brandt MG**, Parr J, Fung K. A needs assessment of undergraduate education in otolaryngology amongst family medicine residents. *Journal of Otolaryngology - Head and Neck Surgery*. 2008; 37(5):668-75.

**Brandt MG**, Moore CC, Conlin AE, Stein J, Doyle PC. A pilot randomized control trial of scar repigmentation with UV light and dry tattooing. *Otolaryngology – Head and Neck Surgery*. 2008; 139(6):769-74.

**Brandt MG**, Moore CC, Doyle PC. Clinical evaluation of a novel internal nasal dilation stent for the improvement of nasal breathing. *Otolaryngology – Head and Neck Surgery*. 2008; 138(5):626-32.

**Brandt MG**, Wright ED. The silent sinus syndrome is a form of chronic maxillary atelectasis: a systematic review of all reported cases. *American Journal of Rhinology*. 2008; 22(1):68-73.

**Brandt MG**, Higgins K. Secondary renal cell carcinoma of the head and neck. *The Journal of Otolaryngology - Head and Neck Surgery*. 2007 Dec; 36(3):E85-7.

**Brandt MG**, Moore CC, Jordan K. A randomized control trial of fluorescence guided surgical excision of nonmelanotic cutaneous malignancies. *Journal of Otolaryngology - Head and Neck Surgery*. 2007 Jun; 36(3):148-55.

**Brandt MG**, Davies ET. Visual-spatial ability, learning modality, and surgical knot tying. *Canadian Journal of Surgery*. 2006; 49(6): 412-16.

Moore CC, MacDonald I, Latham R, **Brandt MG**. Septopalatal protraction for correction of nasal septal deformity in cleft palate infants. *Otolaryngology – Head and Neck Surgery* 2005; 133(6):949-53.

**Brandt MG**, Wright ED. Medical student career choice and mental rotations ability. *Clinical and Investigative Medicine* 2005; 28(3):122-127.

### **Invited scholarly publications & book chapters:**

**Brandt MG**, Moore CC. Nonmelanoma Skin Cancer. Facial Plastic Surgery Clinics of North America. 2019 Feb; 27(1):1-13.

**Brandt MG**, Moore CC. Correction of Facial Scars. In: Symptom Oriented Otolaryngology – Head and Neck Surgery: (Volume 2) Rhinology and Facial Plastics. Chapter 34. Pages 366-373. Ahmad Z, Morton RP, Giles M. Jaypee Brothers Medical Publishers. 2017.

**Brandt MG**, Moore CC. Implants in facial skeletal augmentation. Current Opinion in Otolaryngology & Head and Neck Surgery. 2013 Aug;21(4):396-9.

### **Peer-reviewed grants & research scholarships:**

- 2012      **Western Graduate Research Scholarship – Rehabilitation Sciences**  
Value: \$4756.00  
Project: Development and validation of a novel scar assessment scale  
Role: Principal Investigator  
Co-Investigators: Doyle PC, Moore CC, Parsa V.
- 2007      **Physicians Services Incorporated Foundation Research Grant**  
Value: \$16,000  
Project: A prospective evaluation of the impact of nasal surgery on voice.  
Role: Principal Investigator  
Co-Investigators: Rotenberg BW, Moore CC, Doyle PC.
- 2007      **Royal College of Physicians and Surgeons Medical Education Research Grant**  
Value: \$24,000  
Project: Development of a high-fidelity laryngeal model for surgical education.  
Role: Co-Principal Investigator  
Co-Investigators: Franklin JH, Campbell G.
- 2007      **Physicians Services Incorporated Foundation Research Grant**  
Value: \$36,000  
Project: Atrophy amongst mucosa-only versus muscular-mucosa superiorly based pharyngeal flaps.  
Role: Co-Principal Investigator  
Co-Investigators: Husein M, Matic D, Leung A, Wehrli B, Welch I, Doyle PC.

- 2007      **Karl Storz Research Equipment/Supply Grant**  
 Value: \$2000  
 Project: The impact of nasal surgery on voice.  
 Role: Principal Investigator  
 Co-Investigators: Rotenberg BW, Moore CC, Doyle PC.
- 2007      **Xomed – Medtronic Research Equipment/Supply Grant**  
 Value: \$1500  
 Project: The use of computer-assisted learning to acquire psychomotor skills in epistaxis management.  
 Role: Co-Principal Investigator  
 Co-Investigators: Glicksman JT, Moukarbel RV, Rotenberg BW, *Fung K.*
- 2003      **International Association of Cleft Lip and Palate Research Scholarship**  
 Value: \$1000  
 Project: Septopalatal protraction for correction of nasal septal deformity in cleft palate infants.  
 Role: Research Assistant / Summer Studentship Awardee  
 Co-Investigators: Moore CC, MacDonald I, Latham R.
- 2002      **Ethicon, Inc. Research Equipment/Supply Grant**  
 Value: \$1500  
 Project: Visual-spatial ability, learning modality, and surgical knot-tying amongst junior medical students.  
 Role: Principal Investigator  
 Co-Investigator: Davies ET.
- 1999, 2000      **Natural Science and Engineering Research Council of Canada (NSERC) Undergraduate Research Award – Visual Perception**  
 Value: \$3000 x 2 Summers  
 Projects: Visual-spatial abilities in surgical training. Effect of visual-spatial ability on learning of spatially-complex surgical skills. The effect of bench model fidelity on endourologic skills: a randomized controlled study.  
 Role: Research Assistant / Summer Studentship Awardee  
 Supervisor: Hamstra SJ.

**Peer-reviewed travel grants:**

- 2009      **The Triologic Society Resident Travel Grant**  
 Value: \$500  
 Supervisor: Dr. Corey C. Moore  
 Project: A prospective randomized evaluation of scar assessment measures  
 Meeting: 2009 Eastern Section Triological Society Meeting

- 2008      **American Academy of Otolaryngology – Head and Neck Surgery Foundation Resident Leadership Grant**  
Value: \$500  
Meeting: 2008 American Academy of Otolaryngology – Head and Neck Surgery Annual Meeting
- 2008      **The Triologic Society Resident Travel Grant**  
Value: \$500  
Supervisor: Dr. Corey C. Moore  
Project: A clinical evaluation of a novel internal nasal dilation stent  
Meeting: 2008 Eastern Section Triological Society Meeting
- 2007      **Schulich School of Medicine Resident Travel Grant**  
Value: \$1500  
Supervisor: Dr. Corey C. Moore  
Project: A randomized control trial of fluorescence guided excision of nonmelanotic cutaneous malignancies.  
Meeting: 2007 American Academy of Facial Plastic Surgery Annual Meeting

**Invited lectures & presentations:**

**Facial trauma for the Otolaryngologist – Head & Neck Surgeon.**

Brandt MG.

Annual Otolaryngology – Head & Neck Surgery Review Course. Calgary, Alberta, Canada. January 2020.

**Rhinoplasty: the basics for the Royal College examination.**

Brandt MG.

Annual Otolaryngology – Head & Neck Surgery Review Course. Calgary, Alberta, Canada. January 2020.

**Aesthetic Facial Plastic Surgery: the basics for the Royal College examination.**

Brandt MG.

Annual Otolaryngology – Head & Neck Surgery Review Course. Calgary, Alberta, Canada. January 2020.

**Preparing for the Royal College oral examination in facial plastic & reconstructive surgery.**

Brandt MG.

Annual Otolaryngology – Head & Neck Surgery Review Course. Calgary, Alberta, Canada. January 2020.

**Adding Neurotoxin and Filler to your practice.**

Annual Meeting of the Canadian Society of Otolaryngology – Head & Neck Surgery.  
Edmonton, Alberta, June 2019.

**Adding Neurotoxin to your practice.**

2019 Annual McGill Facial Plastic & Reconstructive Surgery Course. McGill Department of Otolaryngology – Head and Neck Surgery. Montreal, Quebec, Canada. May 2019.

**Scar Revision**

2019 Annual McGill Facial Plastic & Reconstructive Surgery Course. McGill Department of Otolaryngology – Head and Neck Surgery. Montreal, Quebec, Canada. May 2019.

**In Office Sterilization and Protocols: Lessons Learned from Public Health**

Panelist: Brandt MG, Sowerby L, Alexander A, Korman M.

Annual Otolaryngology Head and Neck Surgery Update. Toronto, Ontario, Canada, February 2019.

**Facial trauma for the Otolaryngologist – Head & Neck Surgeon.**

Brandt MG.

Annual Otolaryngology – Head & Neck Surgery Review Course. Halifax, Nova Scotia, Canada. January 2019.

**Rhinoplasty: the basics for the Royal College examination.**

Brandt MG.

Annual Otolaryngology – Head & Neck Surgery Review Course. Halifax, Nova Scotia, Canada. January 2019.

**Preparing for the Royal College oral examination in facial plastic & reconstructive surgery.**

Brandt MG.

Annual Otolaryngology – Head & Neck Surgery Review Course. Halifax, Nova Scotia, Canada. January 2019.

**Case-Based Panel Discussion: Skin Cancer**

Panelists: Brandt MG, Brown D, Hekkenberg R, Hanna E, Murray C, Wong R, Hessel A.  
Current Concepts in Head and Neck Surgery. Toronto, Ontario, November, 2018

**Facial trauma for the Otolaryngologist – Head & Neck Surgeon.**

Brandt MG.

Annual Otolaryngology – Head & Neck Surgery Review Course. Halifax, Nova Scotia, Canada. January 2018.

**Rhinoplasty: the basics for the Royal College examination.**

Brandt MG.

Annual Otolaryngology – Head & Neck Surgery Review Course. Halifax, Nova Scotia, Canada. January 2018.

**Preparing for the Royal College oral examination in facial plastic & reconstructive surgery.**

Brandt MG.

Annual Otolaryngology – Head & Neck Surgery Review Course. Halifax, Nova Scotia, Canada. January 2018.

**Office Based Skin Surgery.**

Brandt MG.

What's New in Office Based Procedures in Otolaryngology. Toronto, Ontario, Canada. September 2017.

**Facial Reconstruction Case-Based Panel Discussion.**

Panellist: Brandt MG

Co-Panel Members: Corey Moore, Kathryn Roth, Leigh Sowerby, Scott Hamilton, Aaron Grant, Scott Ernst, Belal Ahmad, Alex Hammond.

Skin Cancer Management Update 2017. Department of Otolaryngology – Head and Neck Surgery, Schulich School of Medicine & Dentistry, Western University. London, Ontario, Canada. May 2017.

**Scar Revision**

Brandt MG.

2017 Annual McGill Facial Plastic & Reconstructive Surgery Course. McGill Department of Otolaryngology – Head and Neck Surgery. Montreal, Quebec, Canada. May 2017.

**Managing Moles & Cysts of the Head and Neck.**

Brandt MG.

Lumps, Bumps & Looks in the Head and Neck Course. Division of Facial Plastic & Reconstructive Surgery. Department of Otolaryngology – Head and Neck Surgery, Faculty of Medicine, University of Toronto Toronto, Ontario, Canada. April 2017.

**Facial trauma for the Otolaryngologist – Head & Neck Surgeon.**

Brandt MG.

Annual Otolaryngology – Head & Neck Surgery Review Course. Halifax, Nova Scotia, Canada. January 2017.

**Rhinoplasty: the basics for the Royal College examination.**

Brandt MG.

Annual Otolaryngology – Head & Neck Surgery Review Course. Halifax, Nova Scotia, Canada. January 2017.

**Preparing for the Royal College oral examination in facial plastic & reconstructive surgery.**

Brandt MG.

Annual Otolaryngology – Head & Neck Surgery Review Course. Halifax, Nova Scotia, Canada. January 2017.

### **Facial analysis for Rhinoplasty**

Brandt MG.

Annual Clinic Day of the Canadian Academy of Facial Plastic and Reconstructive Surgery. Toronto, Ontario, Canada. October 2016.

### **Planning for Skin Cancer Excisions**

Brandt MG.

Caring for Skin Cancer and the Aging Face in Family Practice. Division of Facial Plastic & Reconstructive Surgery. Department of Otolaryngology – Head and Neck Surgery, Faculty of Medicine, University of Toronto Toronto, Ontario, Canada. June 2016.

### **Scar Revision**

Brandt MG.

2016 Annual McGill Facial Plastic & Reconstructive Surgery Course. McGill Department of Otolaryngology – Head and Neck Surgery. Monreal, Quebec, Canada. May 2016.

### **Functional Rhinoplasty: evidence based management of poor nasal breathing**

Brandt MG.

2016 Septorhinoplasty Update. University of Toronto Department of Otolaryngology – Head and Neck Surgery. Toronto, Ontario, Canada. February 2016.

### **Facial trauma for the Otolaryngologist – Head & Neck Surgeon.**

Brandt MG.

Annual Otolaryngology – Head & Neck Surgery Review Course. Halifax, Nova Scotia, Canada. January 2016.

### **Rhinoplasty: the basics for the Royal College examination.**

Brandt MG.

Annual Otolaryngology – Head & Neck Surgery Review Course. Halifax, Nova Scotia, Canada. January 2016.

### **Preparing for the Royal College oral examination in facial plastic & reconstructive surgery.**

Brandt MG.

Annual Otolaryngology – Head & Neck Surgery Review Course. Halifax, Nova Scotia, Canada. January 2016.

### **Otolaryngology – Head and Neck Surgery Unemployment: a cross-sectional survey of graduating Otolaryngology – Head and Neck Surgery residents.**

Brandt MG.

Annual Meeting of the Canadian Society of Otolaryngology – Head & Neck Surgery, Winnipeg, Manitoba, Canada. June 2015.



### **Cases in Facial Reconstruction**

Brandt MG.

2015 Annual McGill Facial Plastic & Reconstructive Surgery Course. McGill Department of Otolaryngology – Head and Neck Surgery. Montreal, Quebec, Canada. May 2015.

### **Facial trauma for the Otolaryngologist – Head & Neck Surgeon.**

Brandt MG.

Annual Otolaryngology – Head & Neck Surgery Review Course. Halifax, Nova Scotia, Canada. January 2015.

### **Rhinoplasty: the basics for the Royal College examination**

Brandt MG.

Annual Otolaryngology – Head & Neck Surgery Review Course. Halifax, Nova Scotia, Canada. January 2015.

### **Preparing for the Royal College oral examination in facial plastic & reconstructive surgery.**

Brandt MG.

Annual Otolaryngology – Head & Neck Surgery Review Course. Halifax, Nova Scotia, Canada. January 2015.

### **Otolaryngology – Head and Neck Surgery Unemployment: a cross-sectional survey of graduating Otolaryngology – Head and Neck Surgery residents.**

Brandt MG.

Annual Royal College – National Specialty Societies Human Resources for Health Dialogue. Royal College of Physicians and Surgeons of Canada, Ottawa, Ontario, Canada. December 2014.

### **Local flaps in nasal reconstruction**

Brandt MG.

Grand Rounds Presentation. Department of Surgery, Southlake Regional Health Centre, Newmarket, Ontario, Canada. November 2014.

### **Facial analysis**

Brandt MG.

Annual Clinic Day of the Canadian Academy of Facial Plastic and Reconstructive Surgery. Toronto, Ontario, Canada. October 2014.

### **Facial trauma for the Otolaryngologist – Head & Neck Surgeon.**

Brandt MG.

Annual Otolaryngology – Head & Neck Surgery Review Course. Halifax, Nova Scotia, Canada. January 2014.

**Rhinoplasty: the basics for the Royal College examination**

Brandt MG.

Annual Otolaryngology – Head & Neck Surgery Review Course. Halifax, Nova Scotia, Canada. January 2014.

**Preparing for the Royal College oral examination in facial plastic & reconstructive surgery.**

Brandt MG.

Annual Otolaryngology – Head & Neck Surgery Review Course. Halifax, Nova Scotia, Canada. January 2014.

**An evidence based approach to nasal fractures.**

Brandt MG.

Annual Clinic Day of the Canadian Academy of Facial Plastic and Reconstructive Surgery. Toronto, Ontario, Canada. October 2013.

**Facial analysis**

Brandt MG.

Visiting Lecturer Teaching Rounds. Division of Otolaryngology – Head and Neck Surgery, Department of Surgery, McMaster University. Hamilton, Ontario, Canada. October 2013.

**Facial trauma for the Otolaryngologist – Head & Neck Surgeon.**

Brandt MG.

Annual Otolaryngology – Head & Neck Surgery Review Course. Halifax, Nova Scotia, Canada. January 2013.

**Rhinoplasty: the basics for the Royal College examination**

Brandt MG.

Annual Otolaryngology – Head & Neck Surgery Review Course. Halifax, Nova Scotia, Canada. January 2013.

**Preparing for the Royal College oral examination in facial plastic & reconstructive surgery.**

Brandt MG.

Annual Otolaryngology – Head & Neck Surgery Review Course. Halifax, Nova Scotia, Canada. January 2013.

**Nasal anatomy and analysis for rhinoplasty**

Brandt MG.

Annual Clinic Day of the Canadian Academy of Facial Plastic and Reconstructive Surgery. Toronto, Ontario, Canada. October 2012.

### **Local flaps in nasal reconstruction**

Brandt MG.

Visiting Lecturer Teaching Rounds. Division of Otolaryngology – Head and Neck Surgery, Department of Surgery, McMaster University. Hamilton, Ontario, Canada. September 2012.

### **Rhinoplasty: patient selection, anatomy, & analysis.**

Brandt MG.

Canadian Society of Otolaryngology – Head and Neck Surgery / University of Toronto Department of Otolaryngology – Head and Neck Surgery Rhinoplasty Course. Toronto, Ontario, Canada. May 2012.

### **What is a Facial Plastic & Reconstructive Surgeon?**

Brandt MG.

Visiting Lecturer Rounds. Department of Family Medicine, Queens University. Kingston, Ontario, Canada. February 2012.

### **Facial trauma for the Otolaryngologist – Head & Neck Surgeon.**

Brandt MG.

Annual Otolaryngology – Head & Neck Surgery Review Course. Halifax, Nova Scotia, Canada. January 2012.

### **Preparing for the Royal College oral examination in facial plastic & reconstructive surgery.**

Brandt MG.

Annual Otolaryngology – Head & Neck Surgery Review Course. Halifax, Nova Scotia, Canada. January 2012.

### **The history of facial plastic & reconstructive surgery in Canada.**

Brandt MG, Moore CC, Conrad K.

Annual Clinic Day of the Canadian Academy of Facial Plastic and Reconstructive Surgery. Toronto, Ontario, Canada. October 2009.

### **Peer-reviewed podium presentations:**

#### **The aesthetic unit principle.**

Brandt MG, Tan S, Doyle PC, Moore CC

Annual Meeting of the American Academy of Facial Plastic & Reconstructive Surgery. New Orleans, LA, United States of America. October 2013.

#### **Preliminary validation of a novel scale for the objective evaluation of linear scars.**

Brandt MG, Moore CC, Parsa V, Moyer JS, Baker SR, Doyle PC.

Annual Meeting of the American Academy of Facial Plastic & Reconstructive Surgery. Washington, DC, United States of America. September 2012.

**Preliminary validation of a novel scale for the objective evaluation of linear scars.**  
Brandt MG, Moore CC, Parsa V, Moyer JS, Baker SR, Doyle PC.  
International Federation of Facial Plastic Surgery Societies (IFFPSS) VII International Congress. Rome, Italy. May 2012.

**Developing a novel scale for the objective evaluation of linear scars.**  
Brandt MG, Moore CC, Parsa V, Doyle PC.  
Annual Meeting of the Canadian Society of Otolaryngology – Head and Neck Surgery. Victoria, British Columbia, Canada. May 2011.

**The history of facial plastic & reconstructive surgery in Canada.**  
Brandt MG, Moore CC, Conrad K.  
Annual Meeting of the Canadian Society of Otolaryngology – Head and Neck Surgery. Niagara Falls, Ontario, Canada. May 2010.

**A prospective evaluation of perioperative concern amongst patients considering thyroidectomy.**  
Brandt MG, Franklin JH, Osborn HA, Fung K, Yoo J, Doyle PC.  
World Congress on Thyroid Cancer. Toronto, Ontario, Canada. August 2009.

**A prospective evaluation of perioperative concern amongst patients considering thyroidectomy.**  
Brandt MG, Franklin JH, Osborn HA, Fung K, Yoo J, Doyle PC.  
Annual Meeting of the Canadian Society of Otolaryngology – Head and Neck Surgery. Halifax, Nova Scotia, Canada. May 2009.

**Atrophy amongst mucosa only versus muscular mucosa superiorly based pharyngeal flaps.**  
Brandt MG, Husein M, Matic D, Leung A, Wehrli B, Welch I, Doyle PC.  
Junior Investigator Competition, Annual American Cleft Palate – Craniofacial Association Meeting. Scottsdale, Arizona, United States of America. April 2009.

**A prospective randomized evaluation of scar assessment measures.**  
Brandt MG, Moore CC, Micomonaco D, Fung K, Franklin JH, Yoo J, Doyle PC.  
Annual Eastern Section Triologic Society Meeting. Boston, Massachusetts, United States of America. January 2009.

**A needs assessment of undergraduate education in Otolaryngology amongst Family Medicine residents.**  
Glicksman JT, Brandt MG, Parr J, Fung K.  
Annual Meeting of the Canadian Society of Otolaryngology – Head and Neck Surgery. Jasper, Alberta, Canada. May 2008.

**Clinical evaluation of a novel internal nasal dilation stent for the improvement of nasal breathing.**

Brandt MG, Moore CC, Doyle PC.

Annual Eastern Section Triologic Society Meeting. Philadelphia, Pennsylvania, United States of America. January 2008.

**A randomized control trial of fluorescence guided surgical excision of nonmelanotic cutaneous malignancies.**

Brandt MG, Moore CC, Jordan K.

Poliquin Medtronic-Xomed Resident Research Competition – Annual Meeting of the Canadian Society of Otolaryngology – Head and Neck Surgery. Kelowna, British Columbia, Canada. May 2006.

**Visual spatial ability, learning modality and surgical knot tying.**

Brandt MG, Davies ET.

Annual Meeting of the Royal College of Physicians and Surgeons of Canada. Ottawa, Ontario, Canada. October 2004.

**Medical student career choice and mental rotations ability.**

Brandt MG, Wright ED.

Annual Meeting of the Royal College of Physicians and Surgeons of Canada. Ottawa, Ontario, Canada. October 2004.

**Symptoms, acid exposure, and motility in patients with Barrett's esophagus.**

Brandt MG, Darling GE, Miller L.

Annual Meeting of the Canadian Association of Thoracic Surgeons. London, Ontario, Canada. September 2002.

**Peer-Reviewed Posters:**

Oyewumi M, **Brandt MG**, Carrillo B, Atkinson A, Iglar K, Forte V, Campisi P. Objective evaluation of otoscopy skills among family and community medicine, pediatric, and Otolaryngology Residents. Annual Meeting of the Canadian Society of Otolaryngology – Head and Neck Surgery. Charlottetown, Prince Edward Island, Canada.

Roach V, **Brandt MG**, Moore CC, Wilson TD. The evaluation of 3D videography as a surgical training tool. 2011 University of Western Ontario Annual Anatomy and Cell Biology Research Day. London, Ontario, Canada.

Abdul-Sater L, Henry M, Mjovic T, **Brandt MG**, Franklin JH, Black MJ, Hier MP, Payne RJ. What are thyroidectomy patients really concerned about? A prospective evaluation of perioperative concerns amongst patients considering thyroidectomy. 2010 Annual meeting of the American Academy of Otolaryngology. Boston, Massachusetts, USA.

**Brandt MG**, Moore CC, Micomonaco D, Fung K, Franklin JH, Yoo J, Doyle PC. Clinical evaluation of scars: are we measuring correctly? 2008 Annual meeting of the American Academy of Facial Plastic and Reconstructive Surgery. Chicago, Illinois, USA.

**Brandt MG**, Wright ED. Chronic maxillary atelectasis is the silent sinus syndrome. 2007 Combined Otolaryngology Spring Meeting. San Diego, California, USA.

### **Chaired courses & workshops:**

- 2019      **Complications, Pearls & Pitfalls in Facial Reconstruction**  
Panel Discussion Chair  
Co-Presenters: Moore CC, Taylor SM, Ansari K.  
Annual Meeting of the Canadian Society of Otolaryngology – Head & Neck Surgery. Edmonton, Alberta, June 2019
- 2019      **Case-Based Panel Discussion: Interesting Cases**  
Panel Discussion Chair  
Co-Panelists: Witterick I, Davids T, Lin J  
OTOUpdate 2019  
Toronto, Ontario, February 2019
- 2018      **Facial Plastic & Reconstructive Surgery Paper Presentations**  
Paper Presentation Chair  
Annual Meeting of the Canadian Society of Otolaryngology – Head & Neck Surgery. Quebec City, Quebec, June 2018.
- 2018      **Lumps, Bumps & Looks in the Head and Neck.**  
Course Director  
Accredited 3.5hr CME event covering a broad spectrum of topics in skin cancer, oral pathology, oculoplastic lesions, facial reconstruction, and facial aesthetics. Toronto, Ontario, April, 2018
- 2017      **Nasal reconstruction: a specialist panel on the contemporary reconstruction of the face.**  
Co-Presenters: Moore CC, Taylor SM, Ansari K, Hekkenberg R.  
Annual Clinical Day of the Canadian Academy of Facial Plastic & Reconstructive Surgery. Toronto, Ontario, October 2017.
- 2017      **Complications, Pearls & Pitfalls in Facial Reconstruction**  
Co-Presenters: Moore CC, Taylor SM, Trites J  
Annual Meeting of the Canadian Society of Otolaryngology – Head & Neck Surgery. Saskatoon, Saskatchewan, June 2017.

- 2017 **Facial Plastic & Reconstructive Surgery Paper Presentations**  
Paper Presentation Chair  
Annual Meeting of the Canadian Society of Otolaryngology – Head & Neck Surgery. Saskatoon, Saskatchewan, June 2017.
- 2017 **Nasal reconstruction: a specialist panel on the contemporary reconstruction of the face.**  
Co-Presenters: Moore CC, Taylor SM, Trites J  
Annual Meeting of the Canadian Society of Otolaryngology – Head & Neck Surgery. Saskatoon, Saskatchewan, June 2017.
- 2016 **Lumps, Bumps & Looks in the Head and Neck: An update in Dermatology and Facial Plastic & Reconstructive Surgery.**  
Course Director  
Accredited 3.5hr CME event covering a broad spectrum of topics in skin cancer, facial reconstruction, and facial aesthetics. Toronto, Ontario, April, 2017
- 2016 **Nasal reconstruction: a specialist panel on the contemporary reconstruction of the face.**  
Co-Presenters: Moore CC, Taylor SM, Ansari K, Trites J, Bonaparte J.  
Annual Clinical Day of the Canadian Academy of Facial Plastic & Reconstructive Surgery. Toronto, Ontario, October 2016.
- 2016 **Facial reconstruction: a specialist panel on the contemporary reconstruction of the face.**  
Co-Presenters: Tasman A, Taylor SM, Ansari K, Trites J, Moore CC.  
Annual Meeting of the Canadian Society of Otolaryngology – Head & Neck Surgery. Charlottetown, Prince Edward Island, June 2016.
- 2016 **Caring for skin cancer and facial aesthetics in family practice: An update in Dermatology and Facial Plastic & Reconstructive Surgery.**  
Course Director  
Accredited 6.5hr CME event covering a broad spectrum of topics in skin cancer, facial reconstruction, and facial aesthetics. Toronto, Ontario, June 2016
- 2015 **Facial reconstruction: a specialist panel on the contemporary reconstruction of the face.**  
Co-Presenters: Moore CC, Taylor SM, Ansari K, Trites J.  
Annual Clinical Day of the Canadian Academy of Facial Plastic & Reconstructive Surgery. Toronto, Ontario, October 2015.

- 2015 **Facial reconstruction: a specialist panel on the contemporary reconstruction of the face.**  
Co-Presenters: Sykes J, Taylor SM, Ansari K, Trites J.  
Annual Meeting of the Canadian Society of Otolaryngology – Head & Neck Surgery. Winnipeg, Manitoba, June 2015.
- 2015 **An evidence based approach to nasal trauma.**  
Co-Presenter: Taylor SM.  
Annual Meeting of the Canadian Society of Otolaryngology – Head & Neck Surgery. Winnipeg, Manitoba, June 2015.
- 2014 **Facial reconstruction: a specialist panel on the contemporary reconstruction of the face.**  
Co-Presenters: Taylor SM, Ansari K, Moore CC, Trites J.  
Annual Clinical Day of the Canadian Academy of Facial Plastic & Reconstructive Surgery. Toronto, Ontario, October 2014.
- 2012 **Facial reconstruction: a specialist panel on the contemporary reconstruction of the face.**  
Co-Presenters: Higgins K, Ansari K, Taylor SM, Moore CC.  
Annual Meeting of the Canadian Society of Otolaryngology – Head and Neck Surgery. Toronto, Ontario, May 2012.
- 2012 **A comprehensive review and update in facial plastic surgery.**  
Co-Presenters: Taylor SM, Ellis DAF, Moore CC  
Annual Meeting of the Canadian Society of Otolaryngology – Head and Neck Surgery. Toronto, Ontario, May 2012.
- 2011 **US fellowships: options, immigration and application explained.**  
Co-Presenters: Raza SN, Annand S.  
Annual Meeting of the Canadian Society of Otolaryngology – Head and Neck Surgery. Victoria, British Columbia, May 2011.
- 2011 **Local flap reconstruction for the Otolaryngologist – Head and Neck Surgeon.**  
Annual Meeting of the Canadian Society of Otolaryngology – Head and Neck Surgery. Victoria, British Columbia, May 2011.
- 2011 **Upper & lower facial trauma for the Otolaryngologist – Head and Neck Surgeon.**  
Annual Meeting of the Canadian Society of Otolaryngology – Head and Neck Surgery. Victoria, British Columbia, May 2011.



- 2010 **Facial trauma for the Otolaryngologist – Head and Neck Surgeon.**  
Co-Presenter: Moore CC.  
Annual Meeting of the Canadian Society of Otolaryngology – Head and Neck Surgery. Niagara Falls, Ontario, Canada. May 2010.

**Academic achievements & awards:**

- 2010 **2010 Thomas Martin Golden Throat Award**  
Annual award for the most outstanding scientific presentation amongst Otolaryngology residents at the University of Western Ontario.
- 2010 **2010 Undergraduate Otolaryngology Teaching Award**  
Annual award presented by undergraduate medical students to an Otolaryngology resident for outstanding teaching during their third year clinical clerkship.
- 2009 **2009 Outstanding Surgical Teaching Award**  
Quarterly award for the most outstanding surgical resident educator for medical students completing their clinical clerkship.
- 2009 **2009 C.A. Thompson Award for Scientific Achievement in Otolaryngology**  
Annual award for the most outstanding research project amongst Otolaryngology residents at the University of Western Ontario.
- 2008 **2008 University Students' Council Teaching Honour Roll: Award of Excellence – Medicine**  
Annual university-wide teaching award based upon undergraduate medical student nominations of a lecturer at the University of Western Ontario.
- 2008 **2008 C.A. Thompson Award for Scientific Achievement in Otolaryngology**  
Annual award for the most outstanding research project amongst Otolaryngology residents at the University of Western Ontario.
- 2008 **2008 Undergraduate Otolaryngology Teaching Award**  
Annual award presented by undergraduate medical students to an Otolaryngology resident for outstanding teaching during their third year clinical clerkship.
- 2007 **2007 Thomas Martin Golden Throat Award**  
Annual award for the most outstanding scientific presentation amongst Otolaryngology residents at the University of Western Ontario.

- 2007 **2007 Undergraduate Otolaryngology Teaching Award**  
Annual award presented by undergraduate medical students at the University of Western Ontario to an Otolaryngology resident for outstanding teaching during their third year clinical clerkship.
- 2006 **2006 Paediatric Surgery Resident Research Award (Division of Paediatric Surgery Research Competition)**  
One of two awards for excellence in Paediatric research amongst postgraduate trainees at the University of Western Ontario.
- 2001 **Fourth Year Undergraduate Psychology Prize**  
Awarded to the undergraduate student with the highest GPA amongst graduating B.Sc. (Specialized Honours) Psychology students at York University
- 2001 **Bethune College Masters Prize**  
An annual award to the undergraduate student who has most contributed to Bethune College (York University)
- 2000, 2001 **Bethune College Masters Honour Roll**  
An annual award to undergraduate students who have made significant contributions to Bethune College (York University)
- 1998 – 2001 **Deans Honour Roll**  
York University
- 1999 **Undergraduate Academic Scholarship**  
York University
- 1998 **Merit Award**  
York University

**Professional extracurricular activities:**

- 2019 – Present **Scientific Co-Chair**  
Section of Facial Plastic & Reconstructive Surgery  
International Federation of Otolaryngology Societies 2021 Vancouver Meeting
- 2018 – Present **Reviewer & Podium Presentation Chair**  
Facial Plastic & Reconstructive Surgery Podium Presentation & Poster Submissions  
Canadian Society of Otolaryngology Annual Meeting

- 2017 – Present **Section of Otolaryngology - Delegate**  
Ontario Medical Association
- 2016 – Present **Ontario Regional Representative**  
Canadian Academy of Facial Plastic & Reconstructive Surgery
- 2014 – Present **Co-director; Resident Soft-Tissue Dissection Course**  
Division of Facial Plastic & Reconstructive Surgery  
Department of Otolaryngology – Head and Neck Surgery  
Faculty of Medicine, University of Toronto
- 2014 – Present **Ontario Regional Representative**  
Canadian Society of Otolaryngology – Head and Neck Surgery
- 2011 – 2017 **Fellowship Committee**  
American Academy of Facial Plastic and Reconstructive Surgery
- 2010 – 2017 **Membership & Residency Relations Committee**  
American Academy of Facial Plastic and Reconstructive Surgery
- 2010 – 2017 **Research Committee**  
American Academy of Facial Plastic and Reconstructive Surgery
- 2015– 2016 **Grant Reviewer**  
**Combined Otolaryngology Research Effort (CORE) Grant Review**  
American Academy of Otolaryngology – Head and Neck Surgery
- 2010 – 2016 **Young Physicians Committee**  
American Academy of Facial Plastic and Reconstructive Surgery
- 2014 – 2015 **Grant Reviewer**  
**Combined Otolaryngology Research Effort (CORE) Grant Review**  
American Academy of Otolaryngology – Head and Neck Surgery  
American Academy of Facial Plastic & Reconstructive Surgery
- 2012 – 2016 **Electronic Communication Chair**  
Canadian Society of Otolaryngology – Head and Neck Surgery
- 2004 – 2011 **Interviewer**  
**Schulich School of Medicine Admissions Committee**  
University of Western Ontario
- 2008 - 2009 **Resident Representative, Postgraduate Education Committee**  
Department of Otolaryngology, University of Western Ontario

2007 – 2009 **Resident Representative, University of Western Ontario**  
American Academy of Otolaryngology – Head and Neck Surgery

2007 **Resident Representative, Undergraduate Education Committee**  
Department of Otolaryngology, University of Western Ontario

**Volunteerism:**

2015 **Toronto Indy, Toronto, Ontario, Canada**  
Ontario Race Physicians - Volunteer Otolaryngology – Head and Neck Surgeon to the drivers and race teams at the 2015 Toronto Indy. 10hrs.

2015 **Pan & Parapan American Games, Toronto, Ontario, Canada**  
Volunteer Otolaryngology – Head and Neck Surgeon to the athletes and international delegates to the 2015 Pan Am and Para Pan Am Games. 25 hrs.

2011 **University of Michigan Hope Clinic**  
Combined University of Michigan Departments of Otolaryngology & Plastic Surgery charitable clinic for uninsured patients in the Michigan area.

2009 **Medical Mission to La Ceiba, Honduras**  
University of Michigan medical mission. Provided clinical and operative care to children and adults affected by conditions of the head and neck.

**Journal reviewer:**

2019 – Present **Canadian Medical Association Journal**

2017 – Present **Journal of Surgical Education**

2012 – Present **Anatomical Sciences Education**

2011 – Present **International Forum of Allergy & Rhinology**

2010 – Present **American Journal of Rhinology & Allergy**

2008 – Present **The Laryngoscope**

2007 – Present **Journal of Otolaryngology – Head and Neck Surgery**

### **Professional memberships:**

Canadian Society of Otolaryngology – Head and Neck Surgery (CSOHNS)  
American Academy of Facial Plastic and Reconstructive Surgery (AAFPRS)  
Canadian Academy of Facial Plastic and Reconstructive Surgery (CAFPRS)  
European Academy of Facial Plastic Surgery (EAFPS)  
Royal College of Physicians and Surgeons of Canada  
Canadian Medical Association (CMA)  
Ontario Medical Association (OMA)

### **Licensure & certification:**

2019      Advanced Cardiac Life Support (ACLS®) Provider  
            Basic Life Support (BLS®) Provider

2011      College of Physicians and Surgeons of Nova Scotia  
            Independent Medical Practice License: 18085

2018      American Board of Facial Plastic & Reconstructive Surgery  
            Certification in Facial Plastic & Reconstructive Surgery / Diplomate  
            ABFPRS

2011      American Board of Facial Plastic & Reconstructive Surgery  
            Comprehensive Examination in Facial Plastic & Reconstructive  
            Surgery

2011      College of Physicians and Surgeons of Ontario  
            Independent Medical Practice License: 82477

2010      Advanced Cardiac Life Support (ACLS®) Provider

2010      Royal College of Physicians and Surgeons of Canada  
            Fellowship Examination in Otolaryngology – Head and Neck Surgery  
            (FRCSC)  
            Membership: 673990

2010      United States of America Drug Enforcement Agency (DEA) Narcotic  
            License  
            License: FB2085389

- 2010 State of Michigan  
Independent Medical Practice License: 4301095791
- 2009 United States Medical Licensing Examination (USMLE)  
Step III
- 2008 United States Medical Licensing Examination (USMLE)  
Step II (CS & CK)
- 2007 United States Medical Licensing Examination (USMLE)  
Step I
- 2007 Advanced Trauma Life Support (ATLS®) Instructor
- 2007 Royal College of Physicians and Surgeons of Canada  
Principles of Surgery (POS) Examination
- 2006 Medical Council of Canada (MCC)  
Physician Qualifying Examination Part II  
Licentiate Number: 101164
- 2005 College of Physicians and Surgeons of Ontario  
Education Practice License: 82477
- 2005 Medical Council of Canada (MCC)  
Physician Qualifying Examination Part I
- 2005 Laser Fundamentals & Safety Certification
- 2005 Advanced Trauma Life Support (ATLS®) Provider
- 2005 Advanced Cardiac Life Support (ACLS®) Provider

**Non-academic achievements & awards:**

- 1997 **10<sup>th</sup> Place, Karate, 15<sup>th</sup> World Maccabiah Games**  
Tel Aviv, Israel
- 1996 **Black Belt – 1<sup>st</sup> Dan – Taekwondo**  
International Taekwondo Federation
- 1996 **Black Stripe – 1<sup>st</sup> Kyu – Ninjutsu/Ninpo**  
Genbukan Ninpo Bugei